

Association Between Teeth Development in Panoramic Radiograph and Skeletal Maturity in Lateral Cephalogram

Mehdi Ravadgar,^{1,*} Alireza Mirshekar,² Ehsan Moudi,² and Ali Bijani³

¹Orthodontic Department, Dental Materials Research Center, School of Dentistry, Babol University of Medical Sciences, Babol, IR Iran

²Oral and Maxillofacial Radiology Department, School of Dentistry, Babol University of Medical Sciences, Babol, IR Iran

³Social Determinants of Health Research Center, Babol University of Medical Sciences, Babol, IR Iran

*Corresponding author: Mehdi Ravadgar, Orthodontic Department, Dental Materials Research Center, School of Dentistry, Babol University of Medical Sciences, Babol, IR Iran. Tel: +98-1132291408, Fax: +98-1132291093, E-mail: m_ravadgar@yahoo.com

Received 2014 November 22; Revised 2014 December 30; Accepted 2015 January 27.

Abstract

Background: Using a reliable indicator to identify different phases of skeletal maturation is an important issue in orthodontic diagnosis and treatment planning.

Objectives: The aim of this study was to evaluate the correlation between stages of tooth calcification and cervical vertebral maturation in Iranian individuals.

Patients and Methods: 216 digital panoramic and lateral cephalometry of healthy patients, 99 males and 117 females (aged 8 to 16 years) seeking orthodontic treatment included in the study. To determine dental maturational stage, calcification of the mandibular canine, the first and second premolars and the second molar were assessed according to the method suggested by Demirjian et al. To evaluate the stage of skeletal maturation, cervical vertebral morphologic changes were assessed on lateral cephalometric radiographs according to the method suggested by Baccetti et al. All radiographs were evaluated by two observers and inter- and intra-examiner reliability were examined. Spearman's correlations coefficients were calculated to establish the association between cervical vertebral maturation and teeth calcification. P-values less than 0.001 were considered statistically significant.

Results: All correlation values obtained were statistically significant ($P < 0.001$). Correlations between dental development and skeletal maturity stage due to CVM method ranged from 0.76 to 0.77 ($P < 0.001$) for females and 0.63 to 0.71 ($P < 0.001$) for males. The second molar (0.77) and second premolar (0.71) presented the highest correlation for female and male subjects, respectively.

Conclusions: The relationship between calcification of tooth and maturation of cervical bones was significant. This suggested that tooth calcification stages from panoramic radiographs might be clinically useful as a maturity indicator.

Keywords: Cervical Vertebrae, Cephalometry, Radiography, Panoramic, Tooth Calcification

1. Background

Evaluation of skeletal maturity is an extremely important issue in orthodontic and dentofacial orthopedic diagnosis and treatment planning (1). Estimation of the onset of mandibular growth spurt to initiate functional orthopedic treatment in class II subjects and determining reduced growth rate in subjects undergoing orthognathic surgery are examples that can be cited in this regard (2).

Using chronological age to recognize skeletal developmental stage is a weak growth predictor and to evaluate the skeletal maturational stage physiological age would be more reliable (3).

Various maturational indicators such as increase in body height, menarche and voice changes were used to determine physiological age (4), but hand-wrist radiographs considered by many to be the most accurate and common way to evaluate skeletal maturation until recently (5).

Suggestion of a method by Lamparski et al. in 1972 for evaluation of skeletal maturation according to morphological changes in the cervical vertebra on the lateral cephalometry radiographs evoked great interest, especially regarding reduction of patient radiation dose by eliminating extra hand-wrist radiographs (6).

The CVM method, proposed by Baccetti et al. (1) is the most widely used method to evaluate stages of vertebral maturation and has been proved to be effective to assess adolescent growth peak both in the body height and the mandibular size. This method consists of six maturational stages determined based on cervical vertebrae morphology (c2, c3, c4), (1, 2, 7, 8).

Dental maturity based on tooth emergence or stages of tooth calcification observed in radiographs is also an indicator of the biological maturity of growing children (9). Since tooth eruption can be affected by some environ-

mental factors, evaluation based on tooth calcification is more reliable (10, 11). The method introduced by Demirjian et al. (12) is one of the most common methods used to determine the stages of calcification in several teeth. Through maturation changes, this method categorizes teeth mineralization into eight stages, which are less prone to examiner error than the classifications based on teeth enlargement or size (13).

Accessibility of panoramic and lateral cephalograms in diagnostic records of orthodontic patients, and the fact that some studies have shown correlation between dental maturation stages and skeletal maturity suggest using these radiographs instead of hand wrist radiograph in routine orthodontic and dentofacial orthopedic care (14-16).

2. Objectives

The purpose of the current study was to verify any correlation between the developmental stages of mandibular teeth on the panoramic radiographs according to the Demirjian system (12), and cervical maturity stages based on the CVM method on the lateral cephalograms in an Iranian sample.

3. Patients and Methods

This cross-sectional study enrolled subjects seeking orthodontic treatment. Pre-treatment digital panoramic and lateral cephalometric radiographs of 216 subjects (117 girls and 99 boys) aged 8 to 16 years old were evaluated. Sample size was based on previous studies (17-20). All subjects were chosen from one oral and maxillofacial Radiology Center. All radiographs were taken by Cranex D panoramic unite (Soredex, Helsinki Finland) and analyzed by Digora for Windows (DFW) 2.7 version on Samsung monitor with resolution of 2560 × 1440.

Inclusion criteria were:

- 1- Iranian patients aged 8 to 16 years.
- 2- Pre-treatment digital panoramic and lateral cephalometric radiographs accessible with high clarity and good contrast taken in the same day.
- 3- No missing (except third molar), extraction or anomalies (impaction, transposition, hypodontia) in dentition.
- 4- No history of previous orthodontic treatment.
- 5- No history of trauma or surgery in the neck or dentofacial region affecting dental and skeletal development.
- 6- No congenital oral or maxillofacial anomalies such as cleft lip and palate.
- 7- Good general health with absence of growth, endocrine and nutritional problems.
- 8- Absence of cervical vertebral anomalies.

Panoramic radiographs were studied to determine calcification stages of permanent canine, first and second premolars and the second molar of mandibular teeth on the left side.

Dental maturity was assessed through calcification stages proposed by Demirjian et al. (12), used for stag-

ing tooth calcification from A to H. The characteristics of stages are described in Figure 1. The method proposed by Baccetti et al. (1) was used to evaluate cervical vertebral maturation stages (CVM) on lateral cephalograms of patients. This method analyzes the morphology of 2nd, 3rd, 4th cervical vertebrae and the patient is classified into one of the 6 stages accordingly (Figure 2). The characteristics of stages are described in Table 1.

Chronological age of patients established based on the time started from child's birth to the date radiographs were taken and classified into one of the 8 groups with 1-year intervals.

In all radiographs, patients wore collar aprons and since these are routine diagnostic radiographs for orthodontic treatment, there was not any extra exposure risk.

All radiographs analyzed by two observers (one orthodontist, one oral and maxillofacial radiologist). At the same time, cases with disagreement were studied together to get the agreement.

Correlations between bone maturation and teeth calcification were analyzed by Spearman's correlation and P values less than 0.01 were considered statistically significant. SPSS version 17 for Windows (SPSS Inc., Chicago, IL, USA) was used for statistical analysis.

4. Results

The radiographs of 241 (ranged 8 - 16 years) participants were studied, 4 cleft lip and palate, 1 cleidocranial dysplasia syndrome, 11 previous orthodontic treatment, 4 missing, 2 supernumerary and 2 impaction and 1 bilateral first premolar extraction were excluded from the study.

The number and percentage distribution of subjects in each stage of cervical vertebral maturation from CVMS I to CVMS VI are shown in Table 2. Table 3 shows the percentage distribution of calcification of each tooth at the cervical maturation stages from CVMS I to CVMS VI.

At CVMS I, the canine in stage F showed the highest percentage distribution (60.9 % female, 45.7% male).

At CVMS II, Stage F of the canine in males showed the highest percentage distribution (40%). In females, the canine and second premolar in stage F showed the highest percentage distribution (62.5% - 56.3%).

At CVM III, stage G of the second molar and second premolar showed the highest percentage distribution in males (80% - 60%), stage G of the second molar showed the highest percentage distribution in females (56.5%).

At CVM IV, stage G of the second molar showed the highest percentage distribution in female (75%), stage H of the first premolar showed the highest percentage distribution in males (80%).

At CVM V, stage H of the canine and the second molar and stage G of the second molar showed the highest distribution in males (100 % - 87.5 % - 0 87.5%). In females, stage H of the canine and first premolar showed the highest percentage distribution (96.2 %, 100 %).

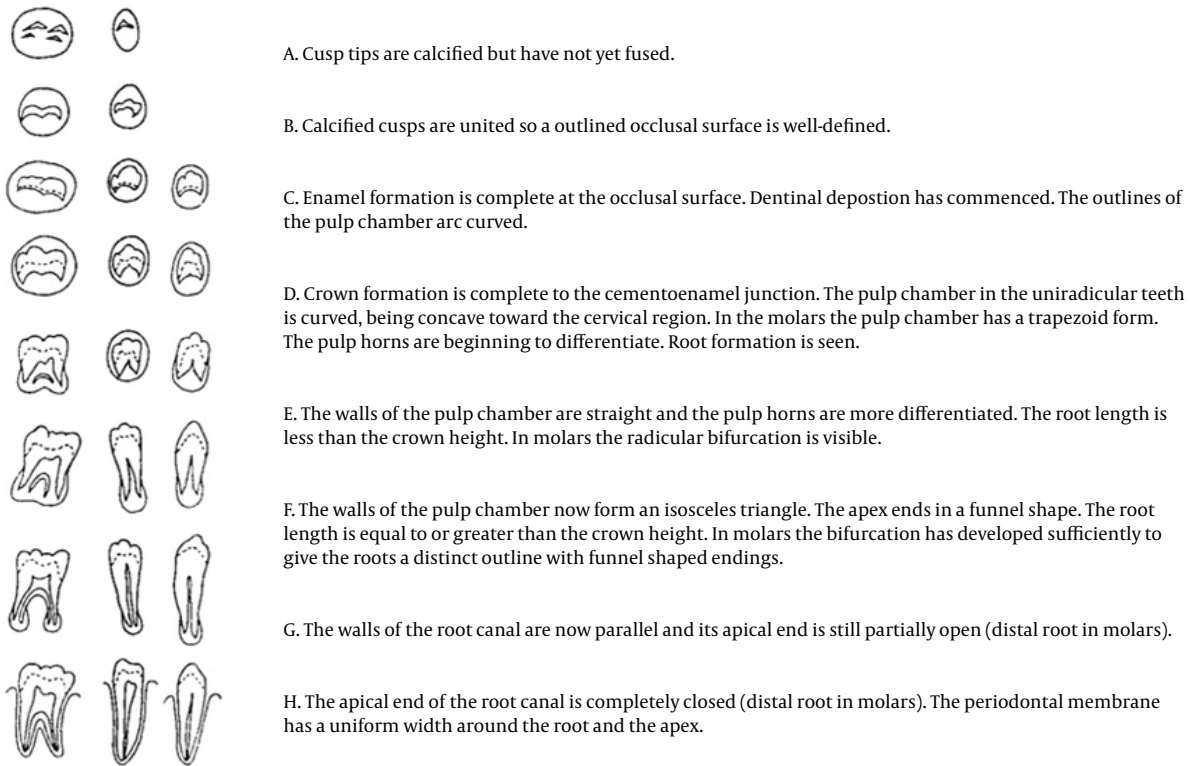


Figure 1. Tooth Calcification Stages, the Demirjian Method

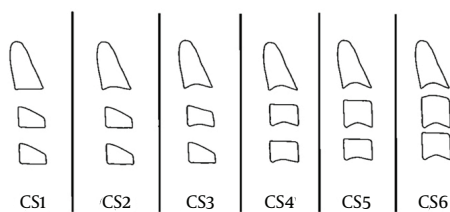


Figure 2. CVM Method Stages (Baccetti et al.)

At CVM VI, stage G of the canine and second molar, stage H of the first and second premolar presented 100% percentage distribution in males, and in females stage H for the canine and second premolar showed 100% distribution.

Spearman rank-order correlation coefficients between skeletal maturity stages of cervical vertebrae and developmental stages of teeth are shown in Table 4.

All the correlations between skeletal and dental stages were statistically significant at $P < 0.01$.

The correlations ranged from 0.76 to 0.77 for females

and 0.63 to 0.71 for males.

The second molar showed the highest correlation, as indicated by an R value of 0.77 ($P < 0.01$) for female and second premolar as indicated by R value of 0.71 ($P < 0.01$) for male subjects, respectively.

Disagreement between observers was examined with weighted kappa statistics for tooth calcification stages. The lowest kappa in tooth calcification stage for the second molar was 0.974 ± 0.013 and for cervical maturation (CVM) 0.983 ± 0.0100 , and it was never more than one stage.

To examine intra-observer reliability, 20 subjects were re-evaluated by both observers and both methods. The interval between two evaluations was 4 weeks. The agreement was assessed by weighted kappa statistics, which was 0.932 ± 0.066 for radiologist and 1 ± 0.000 for orthodontist in the case of cervical maturation (CVM). For tooth calcification stages, canine had the lowest kappa (0.914 ± 0.084) for radiologist, but first premolar had the lowest kappa (0.898 ± 0.100) for orthodontist and it was never more than one stage. These results revealed that the reproducibility of the diagnosis in observers were almost perfect.

Table 1. Characteristics of Cervical Vertebrae Maturation Stages (CVM Method Baccetti et al.)

	Lower Border of c2	Lower Border of c3	Lower Border of c4	Shape of the Body c3	Shape of the Body c4	Time
CS1	Flat	Flat	Flat	Trapezoid	Trapezoid	Peak in mandibular growth would occur on average 2 years after this stage.
CS2	Concave	Flat	Flat	Trapezoid	Trapezoid	Peak in mandibular growth would occur on average 1 year after this stage
CS3	Concave	Concave	Flat	Trapezoid/rectangular horizontal	Trapezoid / rectangular horizontal	Peak in mandibular growth would occur during the year after this stage
CS4	Concave	Concave	Concave	Rectangular horizontal	Rectangular horizontal	The peak in mandibular growth has occurred within 1 or 2 years before this stage.
CS5	Concave	Concave	Concave	At least one of C3 or C4 of the bodies is square	Peak in mandibular growth has ended at least 1 year before this stage	
CS6	Concave	Concave	Concave	Rectangular Vertical	Rectangular vertical	Peak in mandibular growth has ended at least 2 years before this stage

Table 2. Frequency and Percentage of Each CVM Stage

CVM Stages	Values ^a
CS1	58 ± 26.9
CS2	36 ± 16.7
CS3	43 ± 19.9
CS4	31 ± 14.4
CS5	34 ± 15.7
CS6	14 ± 6.5

^aValues are presented as mean ±SD.

Table 3. Percentage Distribution of Calcification of Each Tooth at Each CVM Stage

Tooth Development Stage	Skeletal Maturation Stage(CVM)																	
	CVMS I			CVMS II			CVMS III			CVMS IV			CVMS V			CVMS VI		
	M	F	M	F	M	F	M	F	M	F	M	F	M	F	M	F	M	F
Canine																		
C	0	0	0	0	0	0	0	0	0	0	0	0	0	0	0	0	0	0
D	2.9	0	0	0	0	0	0	0	0	0	0	0	0	0	0	0	0	0
E	22.9	13	15	4.3	0	4.3	0	0	0	0	0	0	0	0	0	0	0	0
F	45.7	60.9	40	62.5	15	17.4	0	12.5	0	0	0	0	0	0	0	0	0	0
G	22.9	21.7	25	18.8	40	47.8	26.7	12.5	0	3.8	100	0	0	0	0	0	0	0
H	5.7	4.3	20	18.8	45	30.4	73.3	75	100	96.2	0	100	0	0	0	0	0	100
First Premolar																		
C	0	0	0	0	0	0	0	0	0	0	0	0	0	0	0	0	0	0
D	5.7	0	0	0	0	0	0	0	0	0	0	0	0	0	0	0	0	0
E	37.1	43.5	25	6.3	0	4.3	0	6.3	0	0	0	0	0	0	0	0	0	0
F	22.9	21.7	35	50	5	30.4	0	6.3	0	0	0	0	0	0	0	0	0	0
G	28.6	34.8	15	31.3	40	39.1	20	25	0	0	0	0	0	0	0	0	0	7.7
H	5.7	0	25	12.5	55	26.1	80	62.5	100	100	100	100	100	100	100	100	100	92.3
Second Premolar																		
C	5.7	4.3	0	0	0	0	0	0	0	0	0	0	0	0	0	0	0	0
D	14.3	13	10	6.3	0	0	0	0	0	0	0	0	0	0	0	0	0	0
E	22.9	30.4	20	18.8	0	4.3	0	6.3	0	0	0	0	0	0	0	0	0	0
F	28.6	30.4	30	56.3	10	43.5	0	12.5	0	0	0	0	0	0	0	0	0	0
G	28.6	21.7	25	6.3	60	34.8	40	56.3	12.5	30.8	0	0	0	0	0	0	0	0
H	0	0	15	12.5	30	17.4	60	25	87.5	69.2	100	100	100	100	100	100	100	100
Second Molar																		
C	5.7	0	0	0	0	0	0	0	0	0	0	0	0	0	0	0	0	0
D	20	26.1	10	6.3	0	0	0	0	0	0	0	0	0	0	0	0	0	0
E	25.7	30.4	30	37.5	0	17.4	0	6.3	0	0	0	0	0	0	0	0	0	0
F	22.9	30.4	30	37.5	15	26.1	6.7	12.5	0	3.8	0	0	0	0	0	0	0	0
G	25.7	13	25	18.8	80	56.5	60	75	87.5	61.5	100	100	100	100	100	100	100	23.1
H	0	0	5	0	5	0	33.3	0	12.5	34.6	0	0	0	0	0	0	0	76.9

Table 4. Spearman Rank-order Correlation Coefficients Between the Skeletal Maturity

Tooth	Spearman's rho		P Value
	Male	Female	
Canine	0.67	0.76	< 0.001
First premolar	0.70	0.76	< 0.001
Second premolar	0.71	0.76	< 0.001
Second molar	0.63	0.77	< 0.001

5. Discussion

Racial and sexual variations in the relationship between calcification stages of individual teeth and skeletal maturity have been reported in previous studies (16, 17, 21-25), so the present study aimed to evaluate the correlation between dental maturation stages in panoramic radiographs and cervical vertebral maturation in lateral cephalograms in an Iranian sample.

Using panoramic radiographs was due to their widespread use and availability in orthodontics and pediatric dental offices.

Though it seems easier to use dental eruption as a dental maturity indicator, calcification stages of teeth instead of eruption were preferred, because tooth formation is proposed as a more reliable indicator for determining dental maturation. Many investigators discarded the use of tooth eruption as an indicator, because it would be affected by systemic, environmental and local influences. The exact timing of teeth eruption could not be determined properly (10-12, 26).

The method introduced by Demirjian et al. (12) was used to assess dental maturation stages, because its criteria is based on distinct details of the form, shape and proportion of the root length in developing teeth rather than just evaluating the teeth length. The latter may be affected by the factor of foreshortening or elongation of the projected images of teeth in dental radiographs (16).

The mandibular canine, first and second premolars and the second molars were investigated as their maturation occurs around the pubertal growth spurt. Mandibular incisors and first molars were not rated, because apical closure had probably occurred in the age range of the study samples (14, 15).

Although development of third molars usually continues for a long time during and after pubertal growth spurt, many previous studies have shown a weak relationship between dental maturation and skeletal maturation stages in these teeth (16, 18, 21); therefore, the third molars were excluded from the study. The maxillary teeth were excluded from the study, because superimposition of anatomic structures in this area would interfere with assessment of accurate developmental stages of teeth (15, 16, 21).

Using cervical vertebral maturation stages (CVM) to identify skeletal maturation stages in lateral cephalographs was due to several reasons. One of the main rea-

sons for the increasing popularity of this method is the common use of these radiographs as a diagnostic tool among orthodontists treating patients with skeletal discrepancies. Another reason is avoidance of additional radiation exposure to patient by preventing extra hand wrist radiograph prescription (1). Previous studies also confirmed that cervical vertebral maturation stage method has the level of reliability compared to hand and wrist radiographs method (27-29).

Since the morphology of the second, third and fourth vertebrae are usually visible even when a protective radiation collar is worn, the 6 stages method proposed by Baccetti et al. was used (1, 2, 30).

The Spearman rank order correlation coefficients between dental calcification and cervical vertebral maturation stages were found to be significant in our study ($P < 0.01$) (Female's = 0.76 to 0.77 male: 0.63 to 0.71). This finding is in accordance with the findings of Sierra et al. (19) ($r = 0.63-0.81$), Krailassiri et al. (16) (female and male subjects, $r = 0.56 - 0.69$, $P < 0.01$), Uysal et al. (21) (female: $r = 0.490 - 0.826$, males: $r = 0.414 - 0.706$, $P < 0.01$), Basaran et al. (15) ($r = 0.60-0.91$) and Perinetti et al. (31) (female and male subjects, $r = 0.67 - 0.72$, $P < 0.01$), Kalinowska et al. (32) ($r = 0.18 - 0.52$ in male, $r = 0.14 - 0.59$ in female, $P < 0.01$) and Valizadeh et al. (26) (female subjects, $r = 0.34 - 0.75$).

To identify skeletal maturity, Sierra et al. (19), Krailassiri et al. (16) and Uysal et al. (21) used hand wrist radiographs, but Basaran et al. (15), Perinetti et al. (31), Kalinowska et al. (32) and Valizadeh et al. (26) used CVM as the skeletal maturity indicator as in our study. The difference in the correlation coefficient in these studies might be related to discrepancies in the number, age and racial background as well as the method of teeth selection (19, 25). For example, in some studies the relationship of incisors, first molars and third molars was evaluated. The studies which assessed the relationship of the selective teeth with skeletal maturity showed greater correlation coefficient. The presence of significant relationship between dental and skeletal maturity in aforementioned studies might suggest that assessment of dental maturity in panoramic radiographs can be helpful in determining skeletal maturity. In the study of Perinetti et al. (31), diagnostic performance of dental maturity for identification of skeletal maturity phase was evaluated using positive likelihood

ratios (LHRs). With a few exceptions, the positive LHRs were less than 2 in most cases.

Results of this study showed that dental maturation assessment is only useful for diagnosis of pre-pubertal growth phase (CS1, CS2) and using panoramic radiograph as a sole diagnostic tool to determine initiation of pubertal skeletal growth should be performed with caution.

The results of our study regarding the relationship between developmental of individual teeth and skeletal development showed that the second premolar in male subjects ($R = 0.71$) and second molars in female subjects ($R = 0.77$) had the highest correlations.

Krailassiri et al. (16) in a Thai sample found highest correlation coefficients for the second premolar in both sexes ($R = 0.66$ in boys and $R = 0.69$ in girls) as it is the same as male subjects of our study.

In the study of Uysal et al. (21) in a Turkish population, the second molar showed the highest relationship with skeletal maturity (boys: $R = 0.826$ and girls: $R = 0.706$); their results in girls are in agreement with our study ($R = 0.77$). Basaran et al. (15) in another Turkish sample found that teeth with greatest correlation with the skeletal maturity were canine in males and first premolar in females.

In a Polish sample, Kalinowska et al. (32) reported canine in males ($R = 0.52$) and the first premolars in females (0.59).

Valizadeh et al. (26) studied the correlation between dental maturity and skeletal development in 400 Iranian females and showed that the first premolars presented the highest relationship with skeletal maturity ($R = 0.75$). They used a 5-stage CVM method instead 6-stage CVM method that used in the present study. This might be an explanation for differences in obtained results of the two studies.

Lack of agreement in the result of different studies regarding teeth, which had the highest correlation with skeletal maturity, may be related to use of different indicators to determine skeletal maturation (Hand wrist radiograph method or CVM method), different sample size, discrepancy in racial background of the studied subjects and different climate and socioeconomic status of patients.

Results of our study showed that at CVM III which is coincided with the initiation of pubertal growth spurt, stage G of the second molar and second premolar (80%, 60% respectively), and stage G of the second molar had the highest percentage distribution in females (56.5%). At CVM IV, stage G of the second molar in females (75%) and stage H of the first premolar (80%) had the highest percentage distribution. Uysal et al. (21) in their study stated that strong correlations were found in the premolars and second molars, which is in agreement with the results of this study.

Chertkow et al. (17) and Chertkow and Fatti (20) reported that stage G of mandibular canine is coincided with stage S in hand wrist radiographs, which is the beginning of the pubertal growth spurt. As in our study, Krailassiri et al. (16), Uysal et al. (21) and Perinetti et al. (31) showed no close relationship with pubertal growth spurt and stage G of mandibular canines.

Valizadeh et al. (26) in their study of 400 Iranian female subjects showed that in most subjects (64.8%) root formation of the canine was completed in the peak of mandibular growth spurt.

Various associations stated in previous studies and the result of our study might be possibly related to different methods and approaches in data collection, and for identification of skeletal or dental maturity indicators, difference in sample size and racial variations.

The results of the present study suggested that the relationship between calcification of teeth and maturation of cervical bones is significant. The second molar presented the highest relationship in females and the second premolar presented the highest in male population.

Acknowledgments

The authors are deeply grateful to postgraduate students of orthodontic Department of Dentistry school of Babol and guidance and support of Dr. Farzin Heravi.

Footnotes

Authors' Contribution: Study concept and design: Alireza Mirshekar, Mehdi Ravadgar; acquisition of data: Mehdi Ravadgar, Alireza Mirshekar, Ehsan Moudi, analysis and interpretation of data: Mehdi Ravadgar, Alireza Mirshekar, Ehsan Moudi, drafting of the manuscript: Mehdi Ravadgar, critical revision of the manuscript for important intellectual content: Mehdi Ravadgar, statistical analysis: Ali Bijani; administrative, technical and material support: Ehsan Moudi; study supervision: Mehdi Ravadgar.

Funding/Support: This study was funded by Babol University of Medical Sciences.

References

- Baccetti T, Franchi L, McNamara JA, editors. The cervical vertebral maturation (CVM) method for the assessment of optimal treatment timing in dentofacial orthopedics.; Seminars in Orthodontics.; 2005; Elsevier; pp. 119-29.
- Baccetti T, Franchi L, McNamara JA, Jr. An improved version of the cervical vertebral maturation (CVM) method for the assessment of mandibular growth. *Angle Orthod.* 2002;72(4):316-23. doi: 10.1043/0003-3219(2002)072<0316:AVOTC>2.0.CO;2. [PubMed: 12169031]
- Fishman LS. Chronological versus skeletal age, an evaluation of craniofacial growth. *Angle Orthod.* 1979;49(3):181-9. doi: 10.1043/0003-3219(1979)049<0181:CVSAAE>2.0.CO;2. [PubMed: 225970]
- Franchi L, Baccetti T, De Toffol L, Polimeni A, Cozza P. Phases of the dentition for the assessment of skeletal maturity: a diagnostic performance study. *Am J Orthod Dentofacial Orthop.* 2008;133(3):395-400. doi: 10.1016/j.ajodo.2006.02.040. [PubMed: 18331939]
- Mito T, Sato K, Mitani H. Predicting mandibular growth potential with cervical vertebral bone age. *Am J Orthod Dentofacial Orthop.* 2003;124(2):173-7. doi: 10.1016/S0889540603004013. [PubMed: 12923513]
- Lamparski DG. Skeletal age assessment utilizing cervical vertebrae. *Am J Orthod.* 1975;67(4):458-9. doi: 10.1016/0002-9416(75)90038-X.
- Baccetti T, Franchi L, McNamara JA, Jr. The cervical vertebral mat-

- uration method: some need for clarification. *Am J Orthod Dentofacial Orthop.* 2003;**123**(1):19A-20A. [PubMed: 12539770]
8. Franchi L, Baccetti T, McNamara JA, Jr. Mandibular growth as related to cervical vertebral maturation and body height. *Am J Orthod Dentofacial Orthop.* 2000;**118**(3):335-40. doi: 10.1067/mod.2000.107009. [PubMed: 10982936]
 9. Nykanen R, Espeland L, Kvaal SI, Krogstad O. Validity of the Demirjian method for dental age estimation when applied to Norwegian children. *Acta Odontol Scand.* 1998;**56**(4):238-44. [PubMed: 9765017]
 10. Fanning EA. Effect of extraction of deciduous molars on the formation and eruption of their successors. *Angle Orthod.* 1962;**32**:44-53.
 11. Nolla CM. The development of the permanent teeth. *J Dent Child.* 1960;**27**:254-66.
 12. Demirjian A, Goldstein H, Tanner JM. A new system of dental age assessment. *Hum Biol.* 1973;**45**(2):211-27. [PubMed: 4714564]
 13. Griffin JT, Malan D. *Age determination of children from radiographic analysis of eight stages in the mineralization of the lower left permanent dentition, excluding third molar.* London Hospital Medical College; 1987.
 14. Rai B, Anand S. Relationship of Hand wrist and panoramic radiographs. *Adv in Med Dent Sci.* 2007;**1**:15-8.
 15. Basaran G, Ozer T, Hamamci N. Cervical vertebral and dental maturity in Turkish subjects. *Am J Orthod Dentofacial Orthop.* 2007;**131**(4):13-20.
 16. Krailassiri S, Anuwongnukroh N, Dechkunakorn S. Relationships between dental calcification stages and skeletal maturity indicators in Thai individuals. *Angle Orthod.* 2002;**72**(2):155-66. doi: 10.1043/0003-3219(2002)072<0155:RBDCSA>2.0.CO;2. [PubMed: 11999939]
 17. Chertkow S. Tooth mineralization as an indicator of the pubertal growth spurt. *Am J Orthod.* 1980;**77**(1):79-91. [PubMed: 6928087]
 18. Engstrom C, Engstrom H, Sagne S. Lower third molar development in relation to skeletal maturity and chronological age. *Angle Orthod.* 1983;**53**(2):97-106. doi: 10.1043/0003-3219(1983)053<0097:LT-MDIR>2.0.CO;2. [PubMed: 6576657]
 19. Sierra AM. Assessment of dental and skeletal maturity. A new approach. *Angle Orthod.* 1987;**57**(3):194-208. doi: 10.1043/0003-3219(1987)057<0194:AODASM>2.0.CO;2. [PubMed: 3477967]
 20. Chertkow S, Fatti P. The relationship between tooth mineralization and early radiographic evidence of the ulnar sesamoid. *Angle Orthod.* 1979;**49**(4):282-8. doi: 10.1043/0003-3219(1979)049<0282:TRBTMA>2.0.CO;2. [PubMed: 292352]
 21. Uysal T, Sari Z, Ramoglu SI, Basciftci FA. Relationships between dental and skeletal maturity in Turkish subjects. *Angle Orthod.* 2004;**74**(5):657-64. doi: 10.1043/0003-3219(2004)074<0657:RBDA SM>2.0.CO;2. [PubMed: 15529501]
 22. Bjork A, Helm S. Prediction of the age of maximum pubertal growth in body height. *Angle Orthod.* 1967;**37**(2):134-43. doi: 10.1043/0003-3219(1967)037<0134:POTAOM>2.0.CO;2. [PubMed: 4290545]
 23. Agarwal DK, Agarwal KN, Upadhyay SK, Mittal R, Prakash R, Rai S. Physical and sexual growth pattern of affluent Indian children from 5 to 18 years of age. *Indian Pediatr.* 1992;**29**(10):1203-82. [PubMed: 1286886]
 24. Hunter WS, Baumrind S, Popovich F, Jorgensen G. Forecasting the timing of peak mandibular growth in males by using skeletal age. *Am J Orthod Dentofacial Orthop.* 2007;**131**(3):327-33. doi: 10.1016/j.ajodo.2006.09.036. [PubMed: 17346587]
 25. Mappes MS, Harris EF, Behrens RG. An example of regional variation in the tempos of tooth mineralization and hand-wrist ossification. *Am J Orthod Dentofacial Orthop.* 1992;**101**(2):145-51. doi: 10.1016/0889-5406(92)70006-V. [PubMed: 1739069]
 26. Valizadeh S, Eil N, Ehsani S, Bakhshandeh H. Correlation between dental and cervical vertebral maturation in Iranian females. *Iran J Radiol.* 2012;**10**(1):1-7. doi: 10.5812/iranjradiol.9993. [PubMed: 23599706]
 27. Pancherz H, Szyska M. Analysis of the cervical vertebrae in place of the hand bones to determine the language and somatic skeletal maturity. 2000;**32**(2):151-61.
 28. Grave K, Townsend G. Cervical vertebral maturation as a predictor of the adolescent growth spurt. *Aust Orthod J.* 2003;**19**(1):25-32. [PubMed: 12790353]
 29. Imanimoghadam M, Heravi F, Khalaji M, Esmaily H. Evaluation of correlation of different methods in determining skeletal maturation group utilizing cervical vertebrae in lateral cephalogram. *J Mash Dent Sch.* 2008;**32**(2):95-102.
 30. Flores-Mir C, Burgess CA, Champney M, Jensen RJ, Pitcher MR, Major PW. Correlation of skeletal maturation stages determined by cervical vertebrae and hand-wrist evaluations. *Angle Orthod.* 2006;**76**(1):1-5. doi: 10.1043/0003-3219(2006)076[0001:COSMSD]2.0.CO;2. [PubMed: 16448261]
 31. Perinetti G, Contardo L, Gabrieli P, Baccetti T, Di Lenarda R. Diagnostic performance of dental maturity for identification of skeletal maturation phase. *Eur J Orthod.* 2012;**34**(4):487-92. doi: 10.1093/ejo/cjr027. [PubMed: 21345927]
 32. Rozylo-Kalinowska I, Kolasa-Raczka A, Kalinowski P. Relationship between dental age according to Demirjian and cervical vertebrae maturity in Polish children. *Eur J Orthod.* 2011;**33**(1):75-83. doi: 10.1093/ejo/cjq031. [PubMed: 20558591]