



Case Report

Deep Margin Elevation With Resin-modified Glass Ionomer in Posterior Adhesive Indirect Restorations Based on Biomimetic Principles: A Case Report

Elham Farhadi¹, Ladan Ranjbar Omrani², Taraneh Estedal³, Elham Ahmadi^{3*}

¹Restorative Department, Dental school, Arak university of medical sciences, Arak, Iran

²Restorative Department, Dental School, Tehran University of Medical Sciences, Tehran, Iran

³Department of Restorative Dentistry, School of Dentistry, Tehran University of Medical Sciences, Tehran, Iran

Article history:

Received: October 14, 2021

Accepted: February 13, 2022

Published: December 7, 2022

*Corresponding author:

Elham Ahmadi,
Email: elham_farhadi2011@yahoo.com



Abstract

A ceramic onlay restoration is a more conservative treatment than full-coverage crowns for endodontically treated teeth (ETT); thus, it helps preserve the tooth structure. Deep margin elevation (DME) is a method to relocate subgingival margins into a more coronal position with resin-modified glass ionomer (RMGI) or direct composite resin before the cementation of the indirect restoration. A 33-year-old male was referred to restore two ETT (teeth N. 46 and 47) with extensive coronal defects extending subgingivally between two teeth. Tooth N. 47 could not undergo a crown lengthening (CL) procedure due to its short root trunk. DME with RMGI was done for both teeth before preparation for ceramic onlays. In this case, by following the principles of biomimetic dentistry, we aimed to restore the tooth defect with a material that bore all functional stresses, in addition to achieving esthetic. It seems that DME in combination with ceramic onlay restoration can be a conservative method to restore ETT in the posterior region. The goal of considering the principles of biomimetic dentistry is to maintain the function of teeth using a good bond to hard tissue that unifies the tooth and its restoration hence distributing the stresses through the tooth as a unit with near-normal functional, biological, and esthetic features.

Keywords: Biomimetic, Dental onlays, Endodontically-treated teeth

Please cite this article as follows: Farhadi E, Ranjbar Omrani, L, Estedal T, Ahmadi E. Deep margin elevation with resin-modified glass ionomer in posterior adhesive indirect restorations based on biomimetic principles: a case report. *Avicenna J Dent Res.* 2022; 14(4):190-193. doi:10.34172/ajdr.2022.532

Introduction

Resorting the crown of endodontically treated teeth (ETT) is challenging. ETT are much more likely to fracture than vital teeth. A cusp coverage restoration is recommended, especially when the defect is extensive (1,2). Partial coverage crowns similar to ceramic onlays can be more conservative than full-coverage crowns for ETT (3,4).

Deep defects in teeth are associated with several clinical challenges, including difficulties in accessing, isolating, and controlling marginal adaptation and emergence profile. Two treatment options are used to manage these defects: crown lengthening (CL) surgery and deep margin elevation (DME). The CL procedure is limited when roots are short and bone removal leads to an undesirable crown/root ratio or exposure to furcation (5). Coronal relocation of subgingival margins, called DME, results in a more coronal margin by bonding several layers of direct resin composite to the deep margins (5,6). We can also use resin-modified glass ionomer (RMGI) in the DME procedure, which is biocompatible and much less sensitive

to the technique and releases fluoride (7-9).

Biomimetic dentistry focuses on replicating natural tooth structures utilizing artificial materials which are called biomimetic materials. These attempts have been made to restore tooth structure by a hard tissue bond and to achieve its full function that unifies the tooth and its restoration and distributes the stresses throughout the tooth with near-normal functional, biological, and esthetic features (10,11).

Case Report

A 33-year-old male was presented to restore endodontically treated right lower molars one day after completing endodontic therapy (Figure 1A-C). Examination revealed deep margins in the distal wall of tooth N.46 and the mesial wall of tooth N.47. Based on clinical and radiographic findings and considering the opposing dentition with zirconia restorations, the fabrication of a direct restoration was ruled out. Following consultation with a periodontist, there were limitations to the CL procedure because when the roots are short, bone removal may lead to an



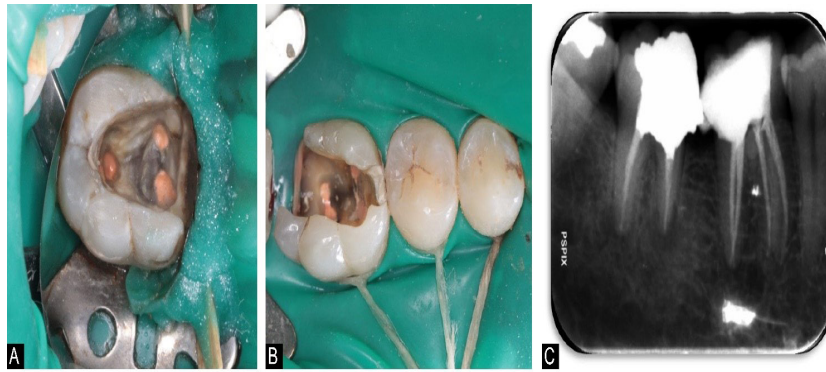


Figure 1. (A) Clinical View of Tooth #47 Before Treatment. (B) Clinical View of Tooth #46 Before Treatment. (C) Periapical Radiograph of Teeth #46 and 47 Before Treatment

undesirable crown/root ratio or exposure to furcation. The patient chose to save the teeth and restore them with indirect adhesive restoration, then teeth were isolated by a rubber dam (DermaDam, Ultradent Products).

Using an RMGI restorative material (Fuji II LC, GC Tokyo, Japan), deep margins were relocated coronally to prevent the violation of biological width in those areas. After placing a Matrix band (Dentsply Sirona, USA) and wooden wedges which were stabilized with a resin material (Gingival barrier), gingival dentin was conditioned (Fuji Conditioner, GC America), and the mixed Fuji II LC material was syringed into the location as much as the capacity of gingival papilla for 2 mm. Then, a LED-based curing light (Valo, Ultradent Products, 1000 mW/cm², South Jordan, USA) was used to cure RMGI for 30 seconds. The RMGI layer was light-cured considering the buccal and lingual aspects for 30 seconds, after eliminating the matrix band (Figure 2). The cavity buildup was then completed with posterior resin composite (Filtek P60, 3M ESPE, Germany) and preparations were made for overlays (12). As observed in Figure 3, the preparation was done using butt joint preparation in the buccal and lingual walls on the enamel surface and slot preparation in the mesial and distal walls in both teeth (13).

Impressions were made using polyvinyl siloxanes

(Express 3M ESPE) in a stock tray along with an impression using alginate (Alginoplast EM, Aroma Fine, Coe Alginate, and Jeltrate Plus) for the opposing arch. Lithium disilicate overlays (IPS e.max Press, Ivoclar Vivadent) were fabricated. Before cementation, restorations were examined for fitness and occlusion. A fine-grit football diamond bur (No. 8379 0014, Komet USA, Rock Hill, USA) was used to adjust restorations. We used diamond silicone polishing points (Dialite, Brasseler, USA) for the polishing step. The inner surface of overlays was etched and rinsed with 5% hydrofluoric acid (IPS Ceramic Etching Gel, Ivoclar Vivadent) for 20 seconds. Afterward, 37% phosphoric acid (BISCO Dental Products, USA) was rubbed on the etched area with a microbrush for 30 seconds and rinsed to eliminate porcelain residuum produced after hydrofluoric acid etching. An ultrasonic (Ultrasound Vita-Sonic II, Germany) was used to clean restorations for 5 minutes. After drying with air, a thin layer of silane (silane, Ultradent products) was applied for 1 minute, and a two-step etch and rinse dentin bonding system (Opti Bond Solo Plus, Kerr Corporation) was applied on the inner surface of the restorations and air-thinned. Next, a light protective barrier was placed on the restorations.

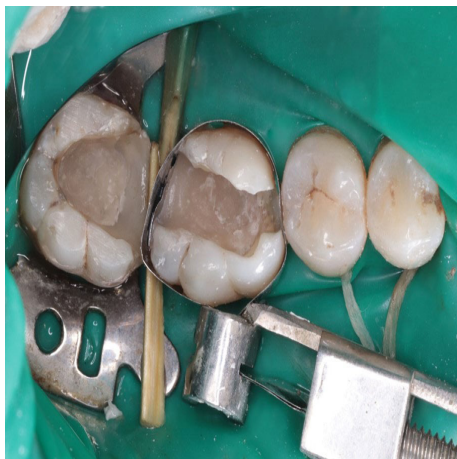

Figure 2. Teeth # 46, 47 After DME Procedure. Note. DEM: Deep margin elevation

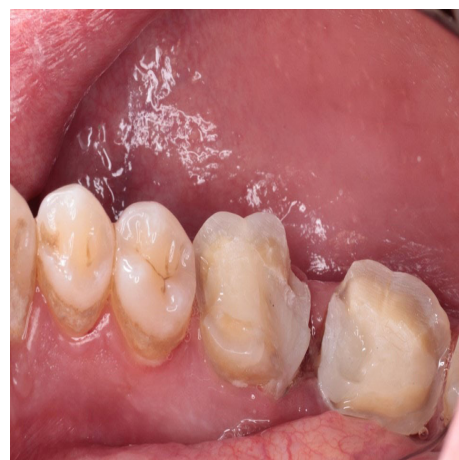

Figure 3. The Cavity Build up With Posterior Resin Composite and in Teeth #46 and 47. Note. The preparation was completed using butt joint preparation in buccal and lingual walls on the enamel surface and slot preparation in the mesial and distal walls in both teeth.

Enamel margins were etched for 15 seconds with the same 37% phosphoric acid, and more etchant was applied to build up material for 10 extra seconds and was rinsed for 15 seconds. High-volume suction was used to dry the surface. We applied two layers of a two-step etch and rinse dentin bonding system (OptiBond Solo Plus, Kerr Corporation) on the preparation surfaces of teeth and thinned them with a microbrush. After air-drying of the second layer and vaporization of its excessive solvent, it was polymerized for 20 seconds using a curing light.

For the cementation step, we used clear shade resin composite cement PANAVIA F.2 (PF2, Kuraray Noritake Dental). The extra resin cement was eliminated with the aid of a microbrush and dental floss. The polymerization of the resin cement was done for 20 seconds considering all aspects using a LED-based curing light. To polymerize any oxygen-inhibited layer, glycerin gel was applied to the margins, and they were light polymerized for 20 seconds again.

A minor occlusal adjustment was made, and the surface was polished using rubber points and fine grit diamond bur (Figure 4). A periapical radiograph was then taken to check marginal adaptation and removal of extra composite resin cement (Figure 5).

The restorations were followed with visual examination and radiographies six months later (Figure 6). The patient was asymptomatic without any evidence of fractures in restorations or teeth, carious lesions, or periodontal inflammation.

Discussion

ETT may have deep subgingival margins which are technically challenging. For instance, placement of rubber dam, making an impression, and cementation are difficult, which affect the survival rate and health of periodontal tissue (14).

CL surgery has limitations in teeth with short root trunks, root proximity, and root concavities. DME is another method to relocate subgingival margins with RMGI or direct composite resin (15). The overall cumulative survival rate of 197 posterior teeth treated by DME technique followed by partial indirect restorations was reported to be 95.9% in 12 years follow-up (16).

For the restoration described in the present study, RMGI restorative material was chosen for the DME procedure due to its ability to adhere chemically to the tooth structure, release of fluoride, biocompatibility to tissues, lower elastic modulus, resistance in streptococcus mutans, minor shrinkage stress, and hydrophilic nature which leads to unaffected microtensile bond strength when it has contact with water (17-19).

The build-up of the pulp chamber was performed (1) to follow the fundamental principle of IDS since it increases microtensile bond strength compared with delayed dentin sealing, (2) to block out the undercuts, (3) to achieve an accurate cavity geometry, and (4) to produce an optimal restoration material thickness (12).

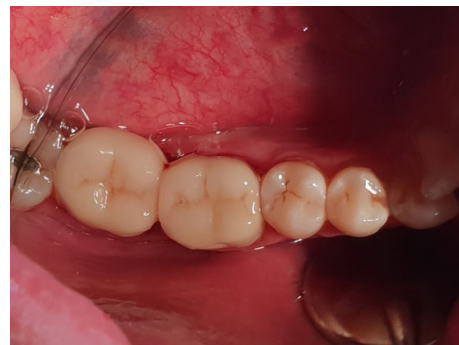

Figure 4. Lithium Disilicate Overlays After Cementation

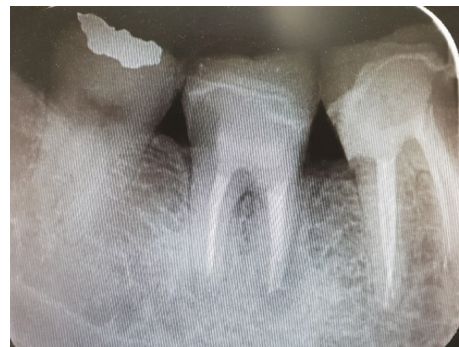

Figure 5. Preapical Radiograph of Teeth #46 and 47 After Overlays Cementation

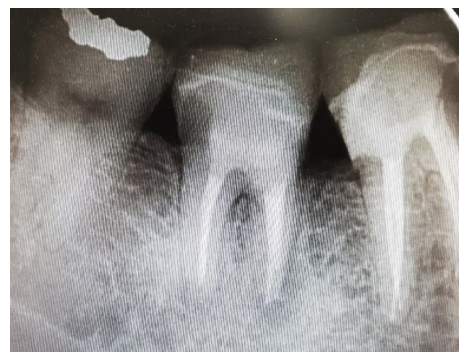

Figure 6. Periapical Radiograph Six Months After Cementation

Author Contributions

Conceptualization: Elham Farhadi.

Data curation: Elham Farhadi.

Formal Analysis: Elham Farhadi.

Funding acquisition: Elham Farhadi.

Investigation: Elham Farhadi.

Methodology: Elham Ahmadi.

Project administration: Elham Ahmadi.

Resources: Ladan Ranjbar Omrani.

Software: Elham Farhadi.

Supervision: Ladan Ranjbar Omrani.

Validation: Elham Ahmadi.

Visualization: Elham Farhadi.

Writing – original draft: Elham Farhadi.

Writing – review & editing: Taraneh Estedlal.

Conflict of Interest Disclosures

The authors declare that they have no conflict of interests.

Ethical Statement

Informed consent was obtained from the patient for the publication

of this report.

References

1. Atlas A, Grandini S, Martignoni M. Evidence-based treatment planning for the restoration of endodontically treated single teeth: importance of coronal seal, post vs no post, and indirect vs direct restoration. *Quintessence Int.* 2019;50(10):772-81. doi: 10.3290/j.qi.a43235.
2. Forster A, Braunitzer G, Tóth M, Szabó BP, Fráter M. In vitro fracture resistance of adhesively restored molar teeth with different MOD cavity dimensions. *J Prosthodont.* 2019;28(1):e325-e31. doi: 10.1111/jopr.12777.
3. Valizadeh S, Ranjbar Omrani L, Deliperi S, Sadeghi Mahounak F. Restoration of a nonvital tooth with fiber reinforce composite (wallpapering technique). *Case Rep Dent.* 2020;2020:9619787. doi: 10.1155/2020/9619787.
4. Abduo J, Sambrook RJ. Longevity of ceramic onlays: a systematic review. *J Esthet Restor Dent.* 2018;30(3):193-215. doi: 10.1111/jerd.12384.
5. Sarfati A, Tirlet G. Deep margin elevation versus crown lengthening: biologic width revisited. *Int J Esthet Dent.* 2018;13(3):334-56.
6. Magne P, Spreafico RC. Deep margin elevation: a paradigm shift. *Am J Esthet Dent.* 2012;2(2):86-96 .
7. Santamaria MP, Suaid FF, Carvalho MD, Nociti FH Jr, Casati MZ, Sallum AW, et al. Healing patterns after subgingival placement of a resin-modified glass-ionomer restoration: a histometric study in dogs. *Int J Periodontics Restorative Dent.* 2013;33(5):679-87. doi: 10.11607/prd.0396.
8. Valizadeh S, Farhadi E, Moradi A, Hashemikamangar SS. Evaluation of the Effect of Cold Plasma Treatment on the Microshear Bond Strength of Composite Resin Restorations to Dentin using Different Adhesive Systems and the Effect of Thermocycling. *The Open Dentistry Journal.* 2021; 31;15(1):734-741. doi: 10.2174/1874210602115010734.
9. Gomes SC, Miranda LA, Soares I, Oppermann RV. Clinical and histologic evaluation of the periodontal response to restorative procedures in the dog. *Int J Periodontics Restorative Dent.* 2005;25(1):39-47.
10. Goswami S. Biomimetic dentistry. *J Oral Res Rev.* 2018;10(1):28-32. doi: 10.4103/jorr.jorr_3_17.
11. Zafar MS, Amin F, Fareed MA, Ghabbani H, Riaz S, Khurshid Z, et al. Biomimetic aspects of restorative dentistry biomaterials. *Biomimetics (Basel).* 2020;5(3):34. doi: 10.3390/biomimetics5030034.
12. Veneziani M. Posterior indirect adhesive restorations: updated indications and the morphology driven preparation technique. *Int J Esthet Dent.* 2017;12(2):204-30.
13. Ferraris F. Posterior indirect adhesive restorations (PIAR): preparation designs and adhesthetics clinical protocol. *Int J Esthet Dent.* 2017;12(4):482-502.
14. Opdam N, Frankenberger R, Magne P. From 'Direct Versus Indirect' Toward an Integrated Restorative Concept in the Posterior Dentition. *Oper Dent.* 2016;41(S7):S27-S34. doi:10.2341/15-126-LIT.
15. Dietschi D, Spreafico R. Current clinical concepts for adhesive cementation of tooth-colored posterior restorations. *Pract Periodontics Aesthet Dent.* 1998;10(1):47-54.
16. Bresser RA, Gerdolle D, van den Heijkant IA, Sluiter-Pouwels LMA, Cune MS, Gresnigt MMM. Up to 12 years clinical evaluation of 197 partial indirect restorations with deep margin elevation in the posterior region. *J Dent.* 2019;91:103227. doi: 10.1016/j.jdent.2019.103227.
17. Dragoo MR. Resin-ionomer and hybrid-ionomer cements: part I. Comparison of three materials for the treatment of subgingival root lesions. *Int J Periodontics Restorative Dent.* 1996;16(6):594-601.
18. Grubbs TD, Vargas M, Kolker J, Teixeira EC. Efficacy of direct restorative materials in proximal box elevation on the margin quality and fracture resistance of molars restored with CAD/CAM onlays. *Oper Dent.* 2020;45(1):52-61. doi: 10.2341/18-098-I.
19. Dragoo MR. Resin-ionomer and hybrid-ionomer cements: part II, human clinical and histologic wound healing responses in specific periodontal lesions. *Int J Periodontics Restorative Dent.* 1997;17(1):75-87.