



# The Rare Eruption of Second Mandibular Permanent Molar in a Seven-Year-Old Girl: A Case Report

Arghavan Kamali Sabeti<sup>1</sup>, Niloufar Entezari Moghaddam<sup>2\*</sup>, Ghazaal Younesi<sup>3</sup>

## Abstract

**Background:** Information on tooth emergence is a key indicator for demonstrating maturity in the diagnosis of certain growth disturbances and an estimation of the chronological age of the children with unknown birth records in forensic dentistry. The association of dental and skeletal maturity with chronologic age among different populations has been investigated by several researchers. Early eruption of permanent molar appears to be a unique finding at such an early chronological age. The present report aimed to present a case of early eruption of mandibular second permanent molar in a seven-year-old girl.

**Case Report:** A seven-year-old girl was referred to the department of pediatric dentistry of Hamadan University with the chief complaint of an extra palatal tooth. Apart from the supernumerary tooth, mandibular second molars and premolars were fully erupted. Radiographic evaluation revealed a closure of the apex of the maxillary and mandibular incisors along with the first molars. For further investigations, the patient was referred to pediatric endocrinologist in order to rule out any systemic disease; however, patient's test results did not show any systemic or hormonal problems. This case is one of the rare cases of early eruption of mandibular second molars at seven with no underlying problems. To our knowledge, no case of early eruption of second permanent molar has been reported in a seven-year-old child and early eruption of second molar appears to be a unique finding at such an early chronological age.

**Conclusions:** Any change in sequence or timing of the normal tooth eruption is not common, and it needs prepared eyes and adequate knowledge to diagnose and examine it in a timely manner.

## \*Correspondence to

Niloufar Entezari  
Moghaddam,  
Shahid Fahmideh Street,  
Hamadan University of  
Medical Sciences, Hamadan  
Iran.  
Postal code: 6517838677,  
Tel: +989123899278,  
Fax: 00988138381085,  
Email: niloufal2@gmail.com

**Keywords:** Eruption  
sequence, Second  
mandibular permanent  
molar, Supernumerary teeth

**Received** January 12, 2021  
**Accepted** February 19, 2021  
**ePublished** June 29 2021

Citation: Kamali Sabeti A, Entezari Moghaddam N, Younesi G. The rare eruption of second mandibular permanent molar in a seven-year-old girl: a case report. Avicenna J Dent Res. 2021;13(2):72-75. doi: 10.34172/ajdr.2021.14.



## Background

Tooth eruption is a natural physiological mechanism by which the teeth sequentially cut through the gingiva into the oral cavity. The word "eruption" comes from the Latin word "eruptio", meaning that momentum production is a closely regulated mechanism involving both the interplay of regulatory genes and a series of interactions between the dental follicle and cells in the surrounding alveolus (1). Growth goes through several variations, using skeletal and dental age to assess the developmental age of a child. Several studies have examined the correlation of dental and skeletal maturity with chronological age in various populations. Chronological age can be correctly calculated by developmental stages, skeletal maturation, secondary sexual characteristics, and dental development. The degree of physiological maturation, which is important for bone ossification, is manifested by the level of skeletal development. Chronological age was calculated by subtracting the date of birth from the date on which the radiograph was taken. The process of Demirjian was

used to measure dental age, which can be estimated by the time of emergence of the tooth in the oral cavity and the tooth developmental pattern. Skeletal age of a child is defined by the maturation of bones. In a young adult, the skeleton bones grow and evolve from fetal life to infancy, puberty, and development completion, which can be seen by x-ray (2). Eruption is the mechanism of growth responsible for bringing a tooth from its crypt location via the alveolar process into the oral cavity to its final occlusion position with its antagonist, a complex process requiring the completion of root development and periodontium establishment and the preservation of a functional occlusion (3). The eruption sequence, influenced by several local and systemic causes, may be delayed or accelerated. While permanent teeth eruption is under important genetic control, this process can be affected by numerous general factors such as sex, socioeconomic status, craniofacial morphology, body composition and metabolic disorders. Most significant disturbances in teeth emergence are caused by systemic

<sup>1</sup>DDS, Assistant Professor of Pediatric Dentistry, Department of Pediatric Dentistry, Faculty of Dentistry, Hamadan University of Medical Sciences, Hamadan, Iran. <sup>2</sup>DDS, Post-Graduate Student of Pediatric Dentistry, Department of Pediatric Dentistry, Faculty of Dentistry, Hamadan University of Medical Sciences, Hamadan, Iran. <sup>3</sup>DDS, Private Practice.

diseases and syndromes (4). At the molecular level, tooth eruption is generally a series of alveolar bone metabolic changes controlled by the adjacent parts of the dental follicle (5). The protein associated with the parathyroid hormone (PTH) has an imperative role in developing the eruption pathway (6). Delayed tooth eruption is a recorded consequence of childhood hypothyroidism, a disorder developed when the thyroid, a major regulator of metabolism, is underactive (7). Conversely, earlier eruption of permanent teeth has been observed in overweight and obese children and those with diabetes mellitus (8-10). Delayed eruption is associated with local and systemic factors such as mucosal barriers-scar tissue including trauma, surgery, supernumerary teeth, injuries to primary teeth, ankyloses as local factors and nutrition: Vitamin D-resistant rickets, celiac disease, hypothyroidism (cretinism), hypopituitarism as systemic factors (11). Early eruption of permanent teeth could be for premature loss of primary teeth if the loss occurs within one year before eruption. But if the extraction is done at a very young age, the eruption of teeth is delayed (12). Trauma and abscess in primary teeth eruption are other key local variables that can cause early eruption of permanent teeth (13).

### Case Presentation

A seven-year-old girl (Figure 1) was registered to the Hamadan University Department of Pediatric Dentistry with the chief complaint of an extra palatal tooth. The additional palatal tooth mass was of great concern to her parents. A supernumerary tooth was located palatally between the left lateral incisor and primary canine teeth in the maxilla. She had Class I occlusal pattern which was seen by intraoral inspection (Figure 2A). An early eruption of left mandibular second premolar, maxillary premolars and, last but not least, early eruption of mandibular second molars (Figure 2A, B) that are supposed to erupt at 11 to 13 were the problems that attracted our attention during the examination (14). Dental maturation of permanent teeth showed marked progression in all teeth and a panoramic radiograph was initially recommended to validate the clinical diagnosis. According to the panoramic radiograph of the patients, mandibular third molars that usually begin calcification at nine have already begun calcification. The radiographic evaluation also revealed the apex closure of maxillary and mandibular incisors, as well as first molars. NOLLA's developmental stages 8 (2/3 of the root completed) of root development in mandibular second molars were also detected in panoramic view (Figure 3). Moreover, mandibular second molars were fully erupted. No remarkable familial history of early eruptions or any syndromes was stated.

The patient was in good systemic conditions according to the history given by her parents, and she was referred to pediatric endocrinologist for hormone testing for further investigations and possible systemic issues due

to her irregular eruption sequence. In serum and urine, thyroid stimulating hormone, PTH, calcium, phosphorous and glucose were tested but nothing abnormal was seen in the tests. Dental panoramic radiograph and cone-beam computed tomography (CBCT) were suggested for a more comprehensive examination of the patient's condition (Figure 4). CBCT axial cut (Figure 5B) showed that due to its short tooth length (17.6 mm) (Figure 3) and its improper location, the extra lateral tooth that was palatally located was extracted. Preventive resin restoration was also performed for deep fissure and initial caries on first permanent molars. As parents were not aware of the condition of the early eruption and believed that their

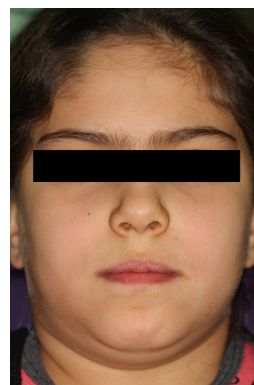

Figure 1. Patient Frontal View.

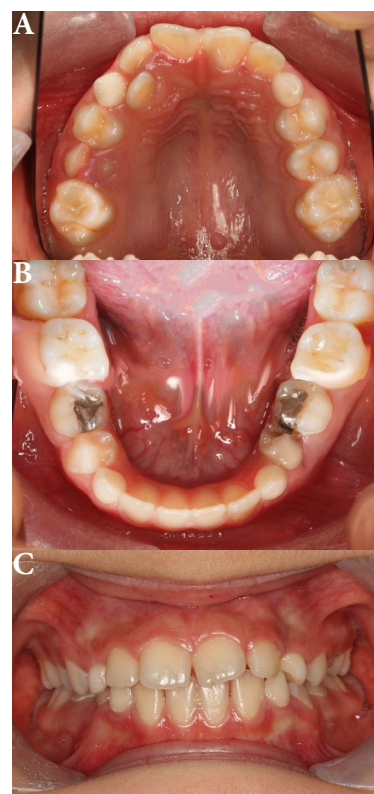


Figure 2. Patient Intraoral Photograph. (A) Supernumerary tooth in left side and premolars in both side of maxilla, (B) Second molars eruption in mandibular arch, (C) Frontal intraoral view.

molars were deciduous teeth, the patient was scheduled to have regular follow-ups. The decision for publishing patient data was taken after receiving an informed consent from her parents.

**Discussion**

During child growth, tooth eruption is an important occurrence and significant deviations from accepted eruption cycle norms are frequently found, which is a source of concern to parents. Dental maturation and eruption through the influence of endocrine advancement are not advanced to the same degree as other biological maturation indicators. In sexual and osseous maturation, normal children who are advanced or retarded are advanced or dentally retarded, though to a less pronounced degree (15). A typical finding is variance in the regular eruption of teeth, but substantial variations from existing standards

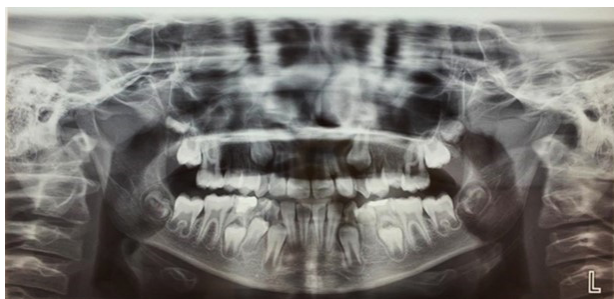

Figure 3. Panoramic View.

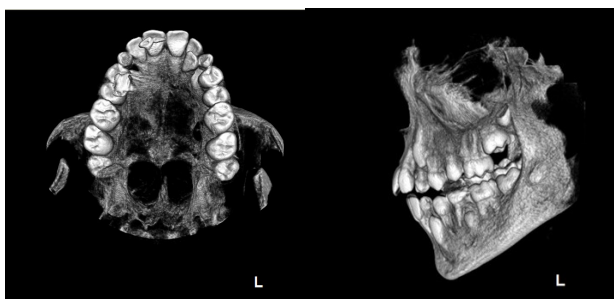

Figure 4. CBCT 3D View.

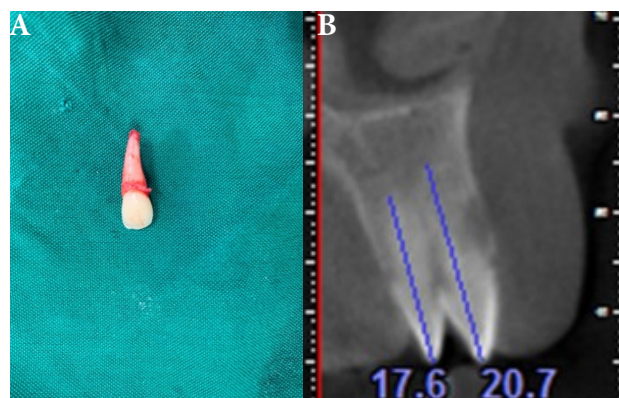


Figure 5. Supernumerary Teeth. (A) Extraction of supernumerary teeth. (B) CBCT axial cut.

should alert the clinician to further examination of the health and development of the patient. Accelerated tooth eruption may be a sign of a systemic disorder or altered craniofacial complex physiology (4). Unlike delayed tooth eruption, accelerated tooth eruption is not as common. Diabetes, obesity and hyperthyroidism can cause speed up tooth eruption (15), which in this case were ruled out by pediatric and internal medicine physicians. Her body mass index was 14.8, which puts her in the 27th percentile indicating that her weight is within normal range. Local factors can also cause early tooth eruption such as premature loss of primary teeth and trauma or abscesses in primary teeth, but in this case there were no primary above second molars. Mandibular second molar normally erupts in girls from the age of 8 years and 11 months to 14 years and 4 months (mean 11.3 years); in boys this is from 9 years and 11 months to 13 years and 11 months (mean 12.0 years) with root completion at 14-15 years (16,17). In the present case the mandibular second molars had fully erupted with NOLLA stage 8 and, to our knowledge, no case of early eruption of mandibular second molar was reported at this age to this date. Normal appearance of third molar crypt is at the age 9 (16), but in this case it had already begun calcification procedure. Apex closure of permanent incisors normally begin at 9-11 years in mandibular and maxilla respectively, but in this case there were closed apex at 7 years. Eruption of left mandibular second premolar and maxillary premolars had also occurred in this case, which usually we expect to erupt at 10-12 years (17).

Different alteration in the sequence of eruption of the permanent teeth can have different clinical signs and different harmful effects on the occlusion such as eruption of second molar before premolars, which may block the second premolar from the arch (18) and in this case, first premolars and second molars in the lower jaw were erupted and patient underwent follow-up so that there would be no growth barrier for the second premolars to erupt.

All the findings in this patient are a rare condition and makes this case unique. Given that the patient had no associated medical history or any symptom of syndromes and early puberty, the accelerated tooth eruption could be attributed to nutrition, diet and environmental factors which need more survey to be clarified.

**Conclusion**

Any alteration in the usual tooth eruption sequence or timing is not a typical occurrence. Only prepared eyes and sufficient expertise can determine the existence of this difference. Early growth and eruptions seldom occur. The pediatric dentist should always consider this situation and, more importantly, its management.

**Conflict of Interest Disclosures**

None declared.

### Acknowledgments

This research did not receive any specific grant from funding agencies in the public, commercial, or not-for-profit sectors.

### Ethical Statement

Informed consent was obtained from the *patient's family* for the publication of this report.

### Authors' Contribution

AK supervised the research. NE performed surgery and follow-ups, NE and GY co-wrote the paper.

### References

- Neto PG, Falcão MC. Eruption chronology of the first deciduous teeth in children born prematurely with birth weight less than 1500 g. *Rev Paul Pediatr*. 2014;32(1):17-23. doi: [10.1590/s0103-05822014000100004](https://doi.org/10.1590/s0103-05822014000100004).
- Palanisamy V, Rao A, Shenoy R, Baranya SS. Correlation of dental age, skeletal age, and chronological age among children aged 9-14 years: a retrospective study. *J Indian Soc Pedod Prev Dent*. 2016;34(4):310-4. doi: [10.4103/0970-4388.191408](https://doi.org/10.4103/0970-4388.191408).
- Adyanthaya A, Ahmed E, Prathyusha P, Afroza K, Johnson AM. A hormonal imbalance-its impact on eruption and exfoliation: a case report. *Glob J Res Anal*. 2019;8(2):1-3.
- Almonaitiene R, Balciuniene I, Tutkuviene J. Factors influencing permanent teeth eruption. Part one--general factors. *Stomatologija*. 2010;12(3):67-72.
- Marks SC Jr, Cahill DR. Regional control by the dental follicle of alterations in alveolar bone metabolism during tooth eruption. *J Oral Pathol*. 1987;16(4):164-9. doi: [10.1111/j.1600-0714.1987.tb02060.x](https://doi.org/10.1111/j.1600-0714.1987.tb02060.x).
- Philbrick WM, Dreyer BE, Nakchbandi IA, Karaplis AC. Parathyroid hormone-related protein is required for tooth eruption. *Proc Natl Acad Sci U S A*. 1998;95(20):11846-51. doi: [10.1073/pnas.95.20.11846](https://doi.org/10.1073/pnas.95.20.11846).
- Young ER. The thyroid gland and the dental practitioner. *J Can Dent Assoc*. 1989;55(11):903-7.
- Sánchez-Pérez L, Irigoyen ME, Zepeda M. Dental caries, tooth eruption timing and obesity: a longitudinal study in a group of Mexican schoolchildren. *Acta Odontol Scand*. 2010;68(1):57-64. doi: [10.3109/00016350903449367](https://doi.org/10.3109/00016350903449367).
- Must A, Phillips SM, Tybor DJ, Lividini K, Hayes C. The association between childhood obesity and tooth eruption. *Obesity (Silver Spring)*. 2012;20(10):2070-4. doi: [10.1038/oby.2012.23](https://doi.org/10.1038/oby.2012.23).
- Lal S, Cheng B, Kaplan S, Softness B, Greenberg E, Goland RS, et al. Accelerated tooth eruption in children with diabetes mellitus. *Pediatrics*. 2008;121(5):e1139-43. doi: [10.1542/peds.2007-1486](https://doi.org/10.1542/peds.2007-1486).
- Suri L, Gagari E, Vastardis H. Delayed tooth eruption: pathogenesis, diagnosis, and treatment. A literature review. *Am J Orthod Dentofacial Orthop*. 2004;126(4):432-45. doi: [10.1016/j.ajodo.2003.10.031](https://doi.org/10.1016/j.ajodo.2003.10.031).
- Rai N, Mathur S, Sandhu M, Sachdev V. Early eruption of maxillary pre molar with turner's hypoplasia in a 5-year-old boy. *J Clin Diagn Res*. 2016;10(8):ZD26-7. doi: [10.7860/jcdr/2016/19242.8287](https://doi.org/10.7860/jcdr/2016/19242.8287).
- Al Mullahi AM, Bakathir A, Al Jahdhami S. Regional early development and eruption of permanent teeth: case report. *Eur Arch Paediatr Dent*. 2017;18(1):59-63. doi: [10.1007/s40368-016-0257-5](https://doi.org/10.1007/s40368-016-0257-5).
- Dean JA, Turner EG. Eruption of the teeth: local, systemic, and congenital factors that influence the process. In: McDonald and Avery's Dentistry for the Child and Adolescent. 10th ed. Mosby; 2016. p. 349-74.
- Garn SM, Lewis AB, Blizzard RM. Endocrine factors in dental development. *J Dent Res*. 1965;44(1):243-58. doi: [10.1177/00220345650440012001](https://doi.org/10.1177/00220345650440012001).
- Contemporary orthodontics, sixth edition. *Br Dent J*. 2019;226(11):828. doi: [10.1038/s41415-019-0429-x](https://doi.org/10.1038/s41415-019-0429-x).
- Ekstrand KR, Christiansen J, Christiansen ME. Time and duration of eruption of first and second permanent molars: a longitudinal investigation. *Community Dent Oral Epidemiol*. 2003;31(5):344-50. doi: [10.1034/j.1600-0528.2003.00016.x](https://doi.org/10.1034/j.1600-0528.2003.00016.x).
- Proffit WR, Sarver DM. Section II: The Development of Orthodontic Problems: Early Stages of Development. In: Contemporary Orthodontics. Mosby; 2018, p.78.

© 2021 The Author(s); Published by Hamadan University of Medical Sciences. This is an open-access article distributed under the terms of the Creative Commons Attribution License (<http://creativecommons.org/licenses/by/4.0>), which permits unrestricted use, distribution, and reproduction in any medium, provided the original work is properly cited.