



Mandibular Ramus Sexual Dimorphism Using Panoramic Radiography

Arash Dabaghi¹ , Abbas Bagheri^{2*}

Abstract

Background: Identification of human remains is the first essential phase of forensic investigation and is significant for subsequent analyses. Mandible is the most dimorphic, largest, and hardest bone of skull and plays a decisive role in sex determination, especially when the complete skull is not available. This study aimed to examine the accuracy of mandibular ramus assessment in sex discrimination using panoramic radiography.

Methods: A total of 135 panoramic radiographs (68 males and 67 females; aged 0-75 years) were retrieved from the database of the Department of Oral and Maxillofacial Radiology, Ahvaz Jundishapur University of Medical Sciences, Iran and divided into five groups :4-14, 16-30, 31-45, 45-60, and 61-75 years. The following four parameters were measured on the radiographs utilizing the mouse-driven method to determine sex: coronoid height (CRH), ramus height (RH), mandibular body height (MBH), and bicondylar breadth (BB). The radiographs were processed using the SCANORA[®] software. Data were analyzed using receiver operating characteristics (ROC) graphs, *t* test, and the IBM SPSS software version 22.0 (IBM Corp., Armonk, N.Y., USA).

Results: The percentage of certainty of each variable regarding the determination of sex from an unknown human mandible bone was as follows: RH=84.6%, CRH=82.4%, BB=73.5%, and MBH=83.8%, indicating that RH alone could categorize the sex in 84.6% of the cases (highest accuracy), CRH in 82.4%, BB in 73.5% (lowest accuracy), and MBH in 83.8%. The average accuracy in sex determination was 89% using all four variables.

Conclusions: All the variables studied in the present study revealed a reliable extent of certainty for sex discrimination of unidentified skeletal remains. The overall accuracy of all variables altogether was 89%.

*Correspondence to

Abbas Bagheri,
Tel: +989370449063,
Email: abbas.bagheri75@
yahoo.com

Keywords: Sexual dimorphism, Panoramic, Forensic dentistry, Mandible, Orthopantomograph, Sex discrimination

Received September 14, 2020

Accepted September 24, 2020

ePublished September 30, 2020



Citation: Dabaghi A, Bagheri A. Mandibular ramus sexual dimorphism using panoramic radiography. Avicenna J Dent Res. 2020;12(3):97-102. doi: 10.34172/ajdr.2020.20.

Background

Identification of human remains is the first essential phase of forensic investigation and is significant for subsequent analyses. Sex determination in adult skeleton is typically the first phase of the identification process and the succeeding steps are age and stature assessment, which are sex dependent. The consistency of sex determination hinges on the completeness of the remains and the grade of sexual dimorphism inherent in the population. In the case that the whole adult skeleton is accessible for analysis, sex can be confirmed up to 100% accuracy, but in the mass casualty disasters where crushed bodies and shattered bones are found, sex identification with 100% precision is not possible and it relies mainly on the existing fragments of skeleton. Skull is the most dimorphic and definite sexed portion of skeleton after pelvis, and it provides accuracy rate up to 92% (1,2).

Mandible is the most dimorphic, largest, and hardest bone of skull and plays a decisive role in sex determination, especially when the complete skull is not available.

Highlights

- ▶ A total of 135 panoramic radiographs were studied.
- ▶ The mean values of all variables were higher for males than females.
- ▶ The average accuracy in sex determination was 89% using all four variables.

A dense layer of compact bone makes mandible very resilient, so it remains well-conserved compared to other bones. Mandible dimorphism is reflected in its shape and size (1-4). Male bones are normally larger and stronger than female bones (2). Masticatory muscle force and facial morphology in males and females and differences in size, strength, and angularity of the masticatory muscles affect the extent of mandibular dimorphism (5). Mandibular ramus measurements have a tendency to display higher sexual dimorphism, and differences between the sexes are commonly more obvious in the mandibular ramus than in the mandibular body (6). Morphometric measurements are considered as accurate methods and can be used in sex

¹Associate Professor, Department of Oral and Maxillofacial Radiology, School of Dental Medicine, Ahvaz Jundishapur University of Medical Sciences, Ahvaz, Iran. ²General Dentist, Department of Oral and Maxillofacial Radiology, School of Dental Medicine, Ahvaz Jundishapur University of Medical Sciences, Ahvaz, Iran.

determination (7).

Oral and maxillofacial radiographic requests have become a routine method in the dental, medical, and hospital clinics. The panoramic radiograph is an expedient and efficient diagnostic imaging projection that provides a comprehensive overview of the maxillofacial complex. Reliability and reproducibility of angular and linear mandible measurements using panoramic radiography have been reported in various studies (8-13).

The aim of the present study was to examine the accuracy of mandibular ramus assessment in sex discrimination using panoramic radiography.

Materials and Methods

A total of 135 panoramic radiographs (68 males and 67 females; aged 4-75 years) were retrieved from the database of the Department of Oral and Maxillofacial Radiology, Ahvaz Jundishapur University of Medical Sciences, Iran and divided into five groups: 4-15, 16-30, 31-45, 45-60, and 61-75 years. The radiographs were related to patients who referred to Ahvaz Department of Oral and Maxillofacial Radiology during 2018-2019. The exclusion criteria included panoramic radiographs with pathologic lesions, deformations, fractures, developmental abnormalities in the mandible, congenitally missing teeth, and panoramic with technical error. The data were properly anonymized and informed consent had been obtained at the time of original data collection.

Panoramic radiographs were taken using Cranex D radiology device (Soredex, Helsinki, Finland) with automatic exposure control and maximum KVP of 70 and 10 MAS and processed using the SCANORA[®] software v. 5.1.2 (Soredex Oy, Tuusula, Finland). All longitudinal measurements were recorded in millimeter. The following four parameters were measured on the radiographs utilizing the mouse-driven method to determine sex:

1. Coronoid height (CRH): projective distance between the coronion (the craniometric point at the tip of the coronoid process of the mandible) and lower wall of the bone (between the end of the lower wall and beginning of mandibular angle);
2. Ramus height (RH): the distance from the most superior lateral point on the ramus to the most inferior lateral point on the ramus tangent;
3. Mandibular body height (MBH): the direct distance from the alveolar process to the inferior border of the mandible, perpendicular to the base at the level of the mental foramen;
4. Bicondylar breadth (BB): the straight distance between the most lateral points on the two condyles (Figure 1). All the age ranges and statical analyses are based on the study by Sambhana et al so that we can compare our results with theirs (14).

All the variables were measured by a sixth-year dental student who was trained to use the same reference points required for obtaining the measurements of the angles and

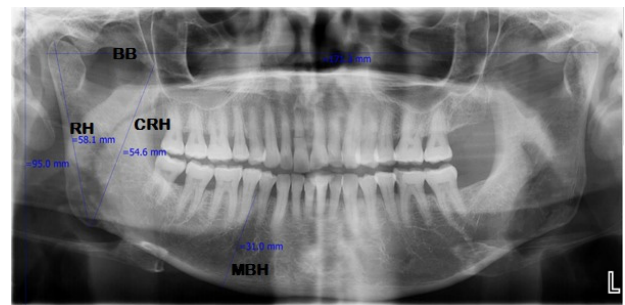


Figure 1. Digital Orthopantomography of Mandibular Variables.

linear distances on each radiograph with dentistry faculty monitors in a four-week period. Descriptive statistics for the mandibular measurements were measured and sensitivity and specificity for all the variables were measured accordingly. Data were analyzed using receiver operating characteristic (ROC) analysis, *t* test, and SPSS software (SPSS, version 22.0, SPSS Inc., Chicago, IL, USA).

Results

In the present study, a total of 135 panoramic radiographs were studied.

As the results of Table 1 shows, in the female group the highest number of samples ($n=30$) were observed in the range of 16-30 years and the lowest rates ($n=3$) were found in the range of 0-15 years. In the male group, the highest number of samples ($n=23$) were observed in the range of 16-30 years and the lowest rates (5 samples) were found in the range of 61-75 years. In total, the highest number of samples was in the range of 16-30 years with 53 samples and the lowest was in the range of 61-75 years with 16 samples.

Table 2 shows the mean and standard deviation of each of the variables in the male and female groups. The mean values of all variables were higher for males than females, indicating that the selected parameters were well-marked for sexual dimorphism assessment. The highest mean difference between the two sexes was related to RH and the lowest mean difference was related to MBH. The values of standard deviation in the male and female groups indicate that the largest point change was related to BB and the smallest range change was related to MBH. Comparisons between male and female groups showed that the range of changes in the variables of CRH, RH, and MBH in the male group was more than female group, and BB changes in female group were more than male group. In general, the largest range of changes in all groups were related to BB and the smallest range of changes were related to MBH.

Table 3 represents the results of regression analysis for dependent variables (gender) and independent variables (CRH, RH, BB, and MBH). The regression coefficient for different variables was as follows: CRH (0.633), RH (0.709), BB (0.476), and MBH (0.723). A correlation coefficient of $r=0.723$ for MBH indicates a stronger degree of linear relationship between MBH and gender.

Table 1. Descriptive Analysis (in mm) of the Mandible in the Studied Groups

Age (years)	Sex	N	CRH	RH	BB	MBH
0-15	Male	7	51.2 ± 2.9	52.4 ± 2.9	163.7 ± 5.0	25.8 ± 1.3
	Female	3	53.4 ± 6.6	46.5 ± 2.4	152.4 ± 4.1	23.3 ± 0.6
16-30	Male	23	54.6 ± 3.5	59.2 ± 4.0	171.6 ± 7.4	28.2 ± 1.9
	Female	30	47.9 ± 2.8	50.4 ± 2.6	163.4 ± 7.4	24.5 ± 2.0
31-45	Male	17	56.3 ± 5.6	59.6 ± 5.0	173.1 ± 7.0	29.8 ± 2.0
	Female	16	49.4 ± 3.4	52.2 ± 2.6	165.3 ± 7.2	24.7 ± 1.2
45-60	Male	16	54.6 ± 2.6	61.0 ± 4.4	171.5 ± 8.2	29.3 ± 2.6
	Female	7	47.4 ± 4.9	50.3 ± 4.1	162.8 ± 5.1	24.7 ± 1.7
61-75	Male	5	53.0 ± 4.7	58.2 ± 5.0	170.7 ± 8.0	29.3 ± 2.2
	Female	11	46.0 ± 3.4	51.1 ± 3.6	161.0 ± 9.3	23.9 ± 1.3

Table 2. Mean Values and Standard Deviations of CRH, RH, BB, and MBH in the Studied Groups

Group	Variable	Mean	SD
Female	CRH	48.1 ± 3.7	3.7
	RH	50.8 ± 3.1	3.1
	BB	162.9 ± 7.7	7.7
	MBH	24.4 ± 1.7	1.7
Male	CRH	54.6 ± 4.1	4.1
	RH	59.1 ± 4.9	4.9
	BB	171.1 ± 7.5	7.5
	MBH	28.7 ± 2.3	2.3
Total	CRH	51.4	3.9
	RH	55.0	4.1
	BB	167.1	7.6
	MBH	26.6	2.0

The regression coefficient was statistically significant for sexual determination.

The discriminant function analysis for CRH, RH, BB, and MBH variables is reported in Table 4. The results of standardized canonical discriminant function coefficients indicate the relative importance of each variable in sex determination, which had the highest level in MBH and the least in BB. These results are used to construct the actual prediction equation, which can be used to classify new cases. To analyze this, the means of each variable are first multiplied with their unstandardized coefficients and the results are then added together to the constant. If the result is negative and is closer to -1.308, the female gender is identified, but if the result is positive and closer to 1.270 the male gender is identified. The formula extracted is as follows: $-17.4 + (CRH \times 0.055) + (RH \times 0.115) + (BB \times 0.004) + (MBH \times 0.287)$. Multivariate classification and leave-one-out cross validation were used for all calculations.

The results of correct classification for original and cross-validation samples are reported in Table 5. The percentage of certainty of each variable regarding the

determination of sex from an unknown human mandible bone was as follows: RH=84.6%, CRH=82.4%, BB=73.5%, and MBH=83.8%, indicating that RH alone could categorize the sex in 84.6% of the cases (highest accuracy), CRH in 82.4%, BB in 73.5% (lowest accuracy), and MBH in 83.8%. The average accuracy in sex determination using all four variables was 89%. This value is greater than all values when using variables individually, and this accuracy is better in correctly identifying the group of females than males.

ROC curve analysis provides a simple and pure measure of validity and diagnostic accuracy for sex discrimination. The details of the AUC obtained are reported in Table 6. The AUC value in CRH, RH, BB, and MBH variables was 0.884, 0.921, 0.774, and 0.929, respectively. A value of 0.774 for AUC in BB variable indicates that this variable is less capable of sex discrimination compared to other variables.

Discussion

Accurate and reliable identification of gender in the wake of the disaster has led to an increasing demand for the identification of unidentified human remains in forensic files. A significant difference was established in the mandibular plane of males and females and this can give a clue for sexual determination (6). All the studied variables for sexual dimorphism are affected by the size of the mandible, which can be due to genetic factors such as tooth size, or may be influenced by environmental factors such as muscle forces applied to the mandibular bone

Table 3. Regression Analysis for Dependent Variables (Gender) and Independent Variables (CRH, RH, BB, and MBH)

Variable	Unstandardized Coefficients	Standardized Coefficients	R	P Value
CRH	6.483	0.633	0.633	0.000
RH	8.305	0.709	0.709	0.000
BB	8.215	0.476	0.476	0.000
MBH	4.307	0.723	0.723	0.000

Table 4. Discriminant Function Analysis for CRH, RH, BB, and MBH Variables

Variable	Unstandardized Canonical Discriminant Function Coefficients	Standardized Canonical Discriminant Function Coefficients	Structure Matrix	Centroids*	Constant
CRH	0.055	0.220	0.807	Females	-17.400
RH	0.115	0.478	0.775	-1.308	
BB	0.004	0.027	0.630	Males	
MBH	0.287	0.594	0.417	1.270	

*Centroids are the mean discriminant score for each group

Table 5. The Rate of Correct Classifications in the Original and Cross-Validation Samples

Variable	Predicted Group Membership (Original) %		Predicted Group Membership (Cross-validated) %		Accuracy (Original) %	Accuracy (Cross-validated) %
	Male	Female	Male	Female		
CRH	82.6	82.1	82.6	82.1	82.4	82.4
RH	76.8	92.5	76.8	92.5	84.6	84.6
BB	69.6	77.6	69.6	77.6	73.5	73.5
MBH	84.1	83.6	84.1	83.6	83.8	83.8
All character variables together	82.6	95.5	82.6	94.0	89.0	88.2

Table 6. ROC Curve Analysis for Sex Determination

Variable	Area Under the Curve	P Value
CRH	0.884	0.000
RH	0.921	0.000
BB	0.774	0.000
MBH	0.929	0.000

during mastication (6, 15).

Mandible, owing to outer dense compact bone, is considered as the strongest skull structure, and it plays a vital role in sex determination. Mandibular radio-morphometric indices in panoramic radiograph categorize possible interrelationships between these indices and sex and age of the patients. Male and female mandibles are distinguished by general size; bones of males are usually larger and stronger than those of females. Mandible is the last bone to complete growth and there are differences in the stages, velocity, and duration of growth between males and females; thus, it is useful for sex discrimination (1, 16-18). The efficacy of the mandible in sex determination has also been established in many studies (1, 3-6, 9, 16, 19-21).

The present study examined the accuracy of mandibular ramus assessment in sex discrimination using panoramic radiography. Four mandibular measurements were taken for sex determination. Several metric studies have been carried out using various parameters on the dried mandibular bones for sex determination (1). The variables measured in the mandible in radiography are influenced by various factors, such as image magnification, while none of these factors directly affect the dried mandibular bone in direct measurement. Thus, the results of these studies cannot be significantly compared with the present

study and all the further studies have used panoramic radiographs.

Previous studies suggested RH as a parameter with high accuracy in sex determination (16, 20, 21). Sambhana et al reported an accuracy of 64.1% with BB, 74.7% with CRH, 67.4% with MBH, and 70.6% with RH. The average accuracy in determining sex by using all the ten variables was 75.8%. The overall accuracy obtained was lower than that obtained in the present study (14).

Giles concluded that white and Negro mandibles can accurately discriminate sex with approximately 85% reliability using RH discriminant function, which was consistent with the results of the present study (16).

Dayal et al identified RH as the best parameter with 75.8% accuracy in sex determination, which is lower than the present study (20). Franklin et al reported overall accuracy of 95% using 10 discriminant functions in South Africa and also showed that RH and CRH have accuracy of 87.5% in sex discrimination, which was higher than the results of the present study (21).

Steyn and Işcan reported accuracy of 81.5% in sex determination of South African whites using five mandibular measurements (BB, bigonial breadth, minimum ramus breadth, gonion-gnathion length, and total mandibular length), which was in agreement with the results of the present study. They also showed that the bigonial breadth is the least truncated parameter in sex determination, which was consistent with the results of the present study. In this study, it was observed that the transverse measurements in the mandible (BB), previously known as very good parameters for gender differentiation (1.21), showed the lowest predictive power in gender differentiation (22).

In the study by Saini et al (2011), it was reported that five measurement parameters (CRH, projective height

of ramus, condylar height, maximum ramus breadth, minimum ramus breadth) were able to determine sex with 80.2% accuracy, which was consistent with the present study. It was also stated that CRH is the best variable for sex determination, but in the present study RH showed the highest accuracy in sex determination (1).

Thakur et al (23) found that the mean RH levels in males were higher than in females, which were consistent with the results of present study.

Saini obtained the highest accuracy (67.4%) in sex determination using MBH variable. In the present study, MBH was the second strongest variable in sex determination; however, the accuracy value obtained in the present study was higher than that found in the Saini's study (24).

Vodanović et al reported that the three discriminant function variables (mandibular body length, mandibular angle, minimum ramus breadth) were able to accurately differentiate (88.2%) gender in the Croatian population, the results of which were consistent with the present study (7).

Sharma et al obtained 60% overall accuracy in sex determination in the Indian population using three variables (body length, mandibular angle, minimum ramus breadth), which was lower than the present study (25). Wankhede et al examined the discriminant function analysis of mandibles for sex determination from a central Indian population. The studied mandibular variables showed sexual dimorphism with an accuracy of 85.4%, which was in line with the results of the present study (26). Kranjčević et al (2014) concluded that BB variable can provide an average accuracy rate of 69%, which was lower than that of the present study (27). Damara et al showed greatest sexual dimorphism with an accuracy of 83.8% in consideration to the maximum RH, which was consistent with the results of the present study (28).

In the present study, the overall accuracy obtained for sex determination using all variables concurrently was 89%, which was higher than the results of some previous studies (29,30) and consistent with several other studies (1,7, 16, 22, 26, 28, 31, 32).

In the present study, the high sensitivity and specificity with typical cutoff values for each variable were evaluated and the results showed that these measurements were profound parameters for sexual dimorphism and can be applied effectively in forensic dentistry. Furthermore, some other factors may contribute to a lower degree of sexual dimorphism including inherited hormonal factors, endocrine growth factors, and socioeconomic factors (33). Since the present study was a retrospective study, these factors were not addressed in the study.

Conclusions

Sex determination plays an important role in anthropological studies and medico-legal cases. The mandible is unique for forensic identification and

provides considerable idiosyncratic characteristics for sex identification, even in severely burned bodies. In this study, every single parameter provided a certain percentage of certainty in sex determination. All the variables studied in the present study revealed a reliable extent of certainty for sex discrimination of unidentified skeletal remains. The overall accuracy of all variables altogether was 89%.

Authors' Contribution

AB and AD conceived the the idea of the research .
AB carried out the experiment and wrote the manuscript with help and supervision of AD.

Conflict of Interest Disclosures

The authors declare that they have no conflict of interests.

Ethical Statement

The present analytical epidemiological study was approved by the Research Ethics Committee of Ahvaz Jundishapur University of Medical Sciences (ethical code: IR.AJUMS.REC.1398.091).

Funding/Support

There was no funding/support for the study.

Acknowledgments

This research has been extracted from a PhD thesis (registration code: 330095313). The authors would like to express their deepest gratitude to Ahvaz Jundishapur University of Medical Sciences, School of Dental Medicine for technical assistance.

References

1. Saini V, Srivastava R, Rai RK, Shamal SN, Singh TB, Tripathi SK. Mandibular ramus: an indicator for sex in fragmentary mandible. *J Forensic Sci.* 2011;56 Suppl 1:S13-6. doi: [10.1111/j.1556-4029.2010.01599.x](https://doi.org/10.1111/j.1556-4029.2010.01599.x).
2. Scheuer L. Application of osteology to forensic medicine. *Clin Anat.* 2002;15(4):297-312. doi: [10.1002/ca.10028](https://doi.org/10.1002/ca.10028).
3. Durić M, Rakocević Z, Donić D. The reliability of sex determination of skeletons from forensic context in the Balkans. *Forensic Sci Int.* 2005;147(2-3):159-64. doi: [10.1016/j.forsciint.2004.09.111](https://doi.org/10.1016/j.forsciint.2004.09.111).
4. Hu KS, Koh KS, Han SH, Shin KJ, Kim HJ. Sex determination using nonmetric characteristics of the mandible in Koreans. *J Forensic Sci.* 2006;51(6):1376-82. doi: [10.1111/j.1556-4029.2006.00270.x](https://doi.org/10.1111/j.1556-4029.2006.00270.x).
5. Franklin D, O'Higgins P, Oxnard CE, Dadour I. Discriminant function sexing of the mandible of indigenous South Africans. *Forensic Sci Int.* 2008;179(1):84.e1-5. doi: [10.1016/j.forsciint.2008.03.014](https://doi.org/10.1016/j.forsciint.2008.03.014).
6. Humphrey LT, Dean MC, Stringer CB. Morphological variation in great ape and modern human mandibles. *J Anat.* 1999;195 Pt 4:491-513. doi: [10.1046/j.1469-7580.1999.19540491.x](https://doi.org/10.1046/j.1469-7580.1999.19540491.x).
7. Vodanović M, Dumančić J, Demo Ž, Mihelić D. Determination of sex by discriminant function analysis of mandibles from two Croatian archaeological sites. *Acta Stomatol Croat.* 2006;40(3):263-77.
8. Sassouni V. Dentofacial radiography in forensic dentistry. *J Dent Res.* 1963;42(1):274-302. doi: [10.1177/00220345630420012901](https://doi.org/10.1177/00220345630420012901).
9. Schulze R, Kruppenauer F, Schalldach F, d'Hoedt B. Precision and accuracy of measurements in digital panoramic radiography. *Dentomaxillofac Radiol.* 2000;29(1):52-6. doi:

- 10.1038/sj/dmfr/4600500.
10. Larheim TA, Svanaes DB, Johannessen S. Reproducibility of radiographs with the orthopantomograph 5: tooth-length assessment. *Oral Surg Oral Med Oral Pathol.* 1984;58(6):736-41. doi: [10.1016/0030-4220\(84\)90045-8](https://doi.org/10.1016/0030-4220(84)90045-8).
 11. Chole RH, Patil RN, Balsaraf Chole S, Gondivkar S, Gadbaile AR, Yuwanati MB. Association of mandible anatomy with age, gender, and dental status: a radiographic study. *ISRN Radiol.* 2013;2013:453763. doi: [10.5402/2013/453763](https://doi.org/10.5402/2013/453763).
 12. Catić A, Celebić A, Valentić-Peruzović M, Catović A, Kuna T. Dimensional measurements on the human dental panoramic radiographs. *Coll Antropol.* 1998;22 Suppl:139-45.
 13. Vaishali MR, Ganapathy KS, Srinivas K. Evaluation of the precision of dimensional measurements of the mandible on panoramic radiographs. *J Indian Acad Oral Med Radiol.* 2011;23(5):323-7. doi: [10.5005/jp-journals-10011-1160](https://doi.org/10.5005/jp-journals-10011-1160).
 14. Sambhana S, Sanghvi P, Mohammed RB, Shanta PP, Thetay AA, Chaudhary VS. Assessment of sexual dimorphism using digital orthopantomographs in South Indians. *J Forensic Dent Sci.* 2016;8(3):180. doi: [10.4103/0975-1475.195113](https://doi.org/10.4103/0975-1475.195113).
 15. Ongkana N, Sudwan P. Gender difference in Thai mandibles using metric analysis. *Chiang Mai Med J.* 2009;48(2):43-8.
 16. Giles E. Sex determination by discriminant function analysis of the mandible. *Am J Phys Anthropol.* 1964;22(2):129-35. doi: [10.1002/ajpa.1330220212](https://doi.org/10.1002/ajpa.1330220212).
 17. O'Shaughnessy PE. Introduction to forensic science. *Dent Clin North Am.* 2001;45(2):217-27.
 18. Carvalho SP, Brito LM, Paiva LA, Bicudo LA, Crosato EM, Oliveira RN. Validation of a physical anthropology methodology using mandibles for gender estimation in a Brazilian population. *J Appl Oral Sci.* 2013;21(4):358-62. doi: [10.1590/1678-775720130022](https://doi.org/10.1590/1678-775720130022).
 19. de Villiers H. Sexual dimorphism of the skull of the South African Bantu-speaking Negro. *S Afr J Sci.* 1968;64(2):118-24.
 20. Dayal MR, Spocter MA, Bidmos MA. An assessment of sex using the skull of black South Africans by discriminant function analysis. *Homo.* 2008;59(3):209-21. doi: [10.1016/j.jchb.2007.01.001](https://doi.org/10.1016/j.jchb.2007.01.001).
 21. Franklin D, O'Higgins P, Oxnard CE, Dadour I. Determination of sex in South African blacks by discriminant function analysis of mandibular linear dimensions: a preliminary investigation using the zulu local population. *Forensic Sci Med Pathol.* 2006;2(4):263-8. doi: [10.1385/fmp.2:4:263](https://doi.org/10.1385/fmp.2:4:263).
 22. Steyn M, Işcan MY. Sexual dimorphism in the crania and mandibles of South African whites. *Forensic Sci Int.* 1998;98(1-2):9-16. doi: [10.1016/s0379-0738\(98\)00120-0](https://doi.org/10.1016/s0379-0738(98)00120-0).
 23. Thakur KC, Choudhary AK, Jain SK, Kumar L. Racial architecture of human mandible-an anthropological study. *J Evol Med Dent Sci.* 2013;2(23):4177-88. doi: [10.14260/jemds/819](https://doi.org/10.14260/jemds/819).
 24. Saini V. Metric study of fragmentary mandibles in a North Indian population. *Bull Int Assoc Paleodont.* 2013;7(2):157-62.
 25. Sharma M, Gorea RK, Gorea A, Abuderman A. A morphometric study of the human mandible in the Indian population for sex determination. *Egypt J Forensic Sci.* 2016;6(2):165-9. doi: [10.1016/j.ejfs.2015.01.002](https://doi.org/10.1016/j.ejfs.2015.01.002).
 26. Wankhede KP, Bardale RV, Chaudhari GR, Kamdi NY. Determination of sex by discriminant function analysis of mandibles from a Central Indian population. *J Forensic Dent Sci.* 2015;7(1):37-43. doi: [10.4103/0975-1475.150304](https://doi.org/10.4103/0975-1475.150304).
 27. Kranioti EF, García-Donas JG, Langstaff H. Sex estimation of the Greek mandible with the aid of discriminant function analysis and posterior probabilities. *Rom J Leg Med.* 2014;22(2):101-4. doi: [10.4323/rjlm.2014.101](https://doi.org/10.4323/rjlm.2014.101).
 28. Damera A, Mohanalakshmi J, Yellarthi PK, Rezwana BM. Radiographic evaluation of mandibular ramus for gender estimation: retrospective study. *J Forensic Dent Sci.* 2016;8(2):74-8. doi: [10.4103/0975-1475.186369](https://doi.org/10.4103/0975-1475.186369).
 29. Jayachandra Pillai T, Shobha Devi T, Lakshmi Devi CK. Studies on human mandibles. *IOSR J Dent Med Sci.* 2014;13(1):8-15. doi: [10.9790/0853-13120815](https://doi.org/10.9790/0853-13120815).
 30. Punarjeevan Kumar M, Lokanandan S. Sex determination & morphometric parameters of human mandible. *Int J Res Med Sci.* 2013;1(2):93-6. doi: [10.5455/2320-6012.ijrms20130511](https://doi.org/10.5455/2320-6012.ijrms20130511).
 31. Pokhrel R, Bhatnagar R. Sexing of mandible using ramus and condyle in Indian population: a discriminant function analysis. *Eur J Anat.* 2013;17(1):39-42.
 32. Marinescu M, Panaitescu V, Rosu M. Sex determination in Romanian mandible using discriminant function analysis: comparative results of a time-efficient method. *Rom J Leg Med.* 2013;21(4):305-8. doi: [10.4323/rjlm.2013.305](https://doi.org/10.4323/rjlm.2013.305).
 33. Suazo Galdames IC, Zavando Matamala DA, Smith RL. Evaluating accuracy and precision in morphologic traits for sexual dimorphism in malnutrition human skull: a comparative study. *Int J Morphol.* 2008;26(4):877-881. doi: [10.4067/s0717-95022008000400015](https://doi.org/10.4067/s0717-95022008000400015).

© 2020 The Author(s); Published by Hamadan University of Medical Sciences. This is an open-access article distributed under the terms of the Creative Commons Attribution License (<http://creativecommons.org/licenses/by/4.0>), which permits unrestricted use, distribution, and reproduction in any medium, provided the original work is properly cited.