

Comparison of Mast Cell Presence in Inflammatory Periapical Lesions Including Periapical Cyst and Granuloma Using Cd117 (C-KIT)

Setareh Shojaei¹; Shokoofeh Jamshidi^{2,*}; Javad Faradmal³; Khadije Biglari⁴; Saeedeh Khajeh Ahmadi⁵

¹Department of Oral and Maxillofacial Pathology, Faculty of Dentistry, Hamadan University of Medical Sciences, Hamadan, IR Iran

²Department of Oral and Maxillofacial Pathology, Dental Research Center, Faculty of Dentistry, Hamadan University of Medical Sciences, Hamadan, IR Iran

³Department of Biostatistics and Epidemiology, Modeling of Noncommunicable Diseases Research Center, School of Public Health, Hamadan University of Medical Sciences, Hamadan, IR Iran

⁴Faculty of Dentistry, Hamadan University of Medical Sciences, Hamadan, IR Iran

⁵Department of Oral and Maxillofacial Pathology, Dental Research Center, Faculty of Dentistry, Mashhad University of Medical Sciences, Mashhad, IR Iran

*Corresponding author: Shokoofeh Jamshidi, Department of Oral and Maxillofacial Pathology, Dental Research Center, Faculty of Dentistry, Hamadan University of Medical Sciences, Hamadan, P.O. Box: 65176-59114, IR Iran. Tel: +98-8138354140, Fax: +98-8138381085, E-mail: dr.jamshidi39@gmail.com

Received: October 18, 2014; **Revised:** November 1, 2014; **Accepted:** November 30, 2014

Background: Periapical lesions are induced in response to injuries to periapical tissues, which are generally the result of infections within the root canal. Mast cells actively participate to the inflammatory infiltration of periapical granulomas and cysts.

Objectives: The aim of this study was to detect and compare the presence of mast cells in inflammatory periapical lesions, including cysts and granulomas.

Materials and Methods: In this cross-sectional study, 26 samples of inflammatory periapical lesions (17 cysts and nine granulomas) were stained with an immunohistochemical technique using CD117 (C-KIT) antibody to detect mast cells. Then, mast cell count (the number of mast cells in 0.2 mm²) and the intensity of mast cell staining were determined by two board certified pathologists. Fisher exact test and t-test were used for statistical analysis, with P < 0.05 for statistical significance.

Results: Although mast cells were observed in all samples, there were more numerous in periapical granulomas compared to periapical cysts, with no statistically significant difference (P = 0.076). The results also demonstrated that the staining in periapical cysts and granulomas were of strong and moderate intensity, respectively, without any significant difference (P = 0.411).

Conclusions: According to the results of this study, it appears that mast cells are present in all the investigated inflammatory periapical lesions and might play a role in the pathogenesis of these lesions.

Keywords: Mast Cells; Radicular Cyst; Periapical Granuloma; CD117 Antigen

1. Background

The human body responds to physical, chemical and microbiologic injuries via inflammatory reactions. Inflammatory lesions are considered one of the most common pathologic conditions of the jaws (1). Periapical lesions are classified into inflammatory, benign, benign aggressive and malignant lesions (2). When the primary origin of a lesion is a necrotic pulp tissue and the osseous lesion is confined to the area of the involved tooth, the situation is called an inflammatory periapical lesion (1). The majority of periapical lesions (> 90%) are classified as radicular cysts and periapical granulomas (3). Periapical granulomas comprise approximately 75% of inflammatory periapical lesions. From a histopathological viewpoint, these lesions consist of an inflammatory tissue bud, surrounded by fibrotic connective tissue (4). The granulation tissue consists of a dense infiltration of lymphocytes composed of neutrophils, plasma cells, histiocytes, mast cells, basophils and other inflammatory cells (4, 5).

Periapical cysts are the most common cysts of the jaws (50 - 75 % of the cysts of the jaws) (2), which are enclosed by stratified squamous epithelium, and might have exocytosis, spongiosis and hyperplasia. In the connective chorion of a cyst, a mixture of lymphocytes, plasma cells, multi-nucleated giant cells, several rare mast cells and eosinophils, necrotic debris and dystrophic calcifications may be found (4, 5). Of all the cells identified in periapical lesions, mast cells have been observed in the inflammatory infiltration of granulomas and cysts (6, 7). Mast cells comprise almost 4.2 ± 2% of all the cellular infiltrations in periapical lesions (8), and have a major role in inducing hypersensitivity reactions and inflammatory processes (6). It has been suggested that IgE secreted by mast cells has a key role in the pathogenesis of periapical granulomas, anaphylactic reactions and hypersensitivity, and is considered to have an active function in the immunologic process and pathogenesis of these lesions, as well

(9). Mast cells and their secreted enzyme, tryptase, are associated with bone loss during the development of cysts (7). Presence of degranulated mast cells in the vicinity of fibroblasts is an indicative of their possible role in the formation of a fibrotic tissue (6). Mast cells' mediators, including histamine and prostaglandins, cause bone loss, which leads to growth and maturation of cysts (7). In contrast, mast cell tryptase induces fibroblasts to produce collagen. Therefore, these cells are involved in both wound healing and fibrosis (6). It is believed that mast cells contribute to the synthesis of fibrotic tissues by producing hyaluronic acid. On the other hand, mast cell-derived heparin promotes the growth of collagen fibers (6).

There are several techniques to identify mast cells. It appears that staining of mast cells with toluidine blue identifies only those cells which have intact granules. In addition, in immunohistochemical staining with tryptase, basophils are stained similar to mast cells as well, because they can release tryptase. Therefore, tryptase cannot be used to make a distinction between mast cells and basophils. The CD117 antigen (C-KIT) is a membrane glycoprotein produced by the gene KIT (10) and is expressed by several normal tissue cells, including hematopoietic cells, mast cells, melanocytes and the stromal cells of the digestive system (6, 11).

Since the literature shows that CD117 staining probably has a higher sensitivity for the identification of mast cells (6), we used this technique to identify mast cells.

2. Objectives

The aim of this study was to detect and compare the presence of mast cells in periapical granuloma and cyst, by using the CD117 marker.

3. Materials and Methods

In this cross-sectional study, 26 samples from 17 periapical cysts and nine periapical granulomas were evaluated. Paraffin blocks were retrieved from the archives of the Department of Oral and Maxillofacial Pathology, Faculty of Dentistry, Hamadan University of Medical Sciences, Hamadan, Iran. The blocks were re-evaluated by two experienced and board certified pathologists. Afterwards, a 4 µm section was provided from each paraffin block for immunohistochemical staining, to evaluate the expression of CD117 proteins (clone: T595) in mast cells, according to manufacturer's instructions (NOVO CASTRA, Newcastle-upon-Tyne, UK). The paraffin blocks were kept at room temperature for 24 hours, followed by deparaffination by xylene and staining based on manufacturer's instructions, as follows: The samples were first immersed in a citrate solution and placed in a microwave oven, followed by rinsing with distilled water. Thereafter, the samples were placed in a moist environment and immersed in peroxidase, biotinylated link antibody, streptavidin, chromogen and hematoxylin, respectively, interspersed by rinsing in distilled water for 5 minutes. Finally, the samples were placed in absolute alcohol and fixed with Entellan adhesive (Merck-Millipore

Corp., Billerica, Massachusetts, USA). Gastrointestinal stromal tumor tissue (GIST) was used as a positive control for CD117 staining. The initial antibody was eliminated in the negative controls.

Mast cell counts (the number of mast cells in 0.2 mm²) (12) were evaluated in the connective chorion of periapical cysts and periapical granulomas, using the CD117 marker, as follows: At first, under x400 magnification, five areas, with the greatest number of mast cell staining with CD117 marker, were selected as the "hot spots" and photographed using a DP12 digital camera (Model U-TVO/5 XC-3, Olympus Corp., Tokyo, Japan) connected to a microscope (Olympus BX-41, Olympus Corp., Tokyo, Japan). Then, the AnalySIS LS Starter software (Olympus Corp., Tokyo, Japan) was used to count the number of stained mast cells in these areas by two pathologists and the means were calculated.

The intensity of mast cell staining was determined using the Modified Quick Score technique, in which the intensity of staining is classified in four groups, as follows:

Negative: No staining.

Weak: The cells are only visible under high-power magnification.

Moderate: The cells are easily seen under low-power magnification.

Strong: Even under low-power magnification, intense staining of the cells is visible (13).

In this study, quantitative variables were analyzed by t-test and the qualitative ones by Fisher exact test, the SPSS software, version 16 (SPSS Inc., Chicago, IL, USA). In addition, Pearson's correlation coefficient and Intra class correlation were measured to determine to what extent the results of two pathologists' observation were convergent. Statistical significance was defined at $P < 0.05$.

4. Results

Ten periapical cysts and five periapical granulomas [15 samples (57.7%)] belonged to females, whereas seven periapical cysts and four periapical granulomas [11 samples (42.3%)] belonged to males. The Pearson's correlation coefficient between two observers was measured as 0.089 ($P < 0.001$). Meanwhile, intraclass correlation for single measure was 0.978 and for average measures was 0.989. The immunoreactivity of the C-KIT in mast cells in periapical cysts and periapical granulomas is illustrated in Figures 1 and 2.

Means (standard deviations) of age in periapical cysts and granulomas were 28.35 (12.28) and 43.22 (7.19) years, respectively, with a mean age of 33.5 (12.85) years, for all samples. The most commonly involved locations of the samples were the posterior mandible and posterior maxilla, each with eight (30.8%) samples (five periapical cysts and three periapical granulomas in the posterior maxilla and four periapical cysts and four periapical granulomas in the posterior mandible). The least commonly involved location was the anterior maxilla with three (1.53%) periapical cysts. Means (standard deviations) of mast cell

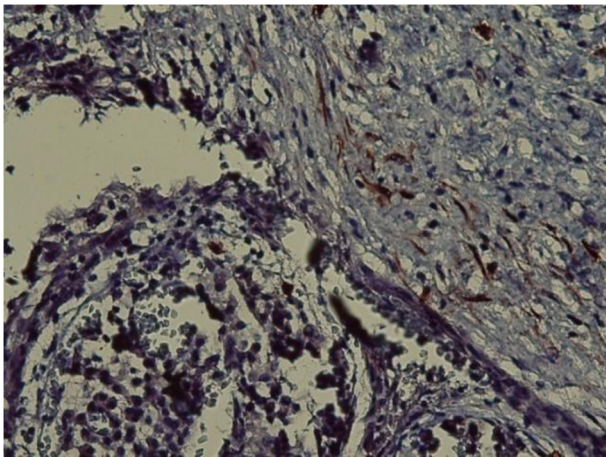


Figure 1. Immunoreactivity of the C-KIT (CD117) in Periapical Cyst ($\times 400$)

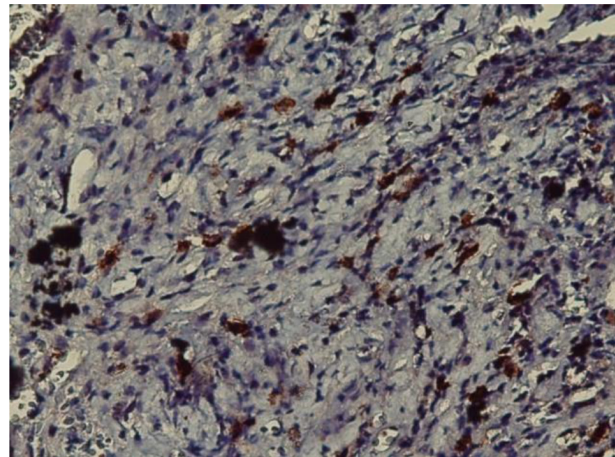


Figure 2. Immunoreactivity of the C-KIT (CD117) in Periapical Granuloma ($\times 400$)

Table 1. The Staining Intensities of Mast Cells With C-Kit (CD117) in Groups ^{a,b}

Lesions staining intensity	Negative	Weak	Moderate	Strong	Total
Periapical cysts	0 (0)	5 (29.4)	2 (11.8)	10 (58.8)	17 (100)
Periapical granulomas	0 (0)	2 (22.2)	4 (44.4)	3 (33.3)	9 (100)
Total	0 (0)	7 (26.9)	6 (23.1)	13 (50)	26 (100)

^a P Value = 0.411, for the exact Fisher test, the weak and moderate staining intensities have been combined in order to calculate P value.

^b All values are presented as No. (%).

counts in periapical cysts and granulomas were 14.75 (5.59) and 21.8 (13.88), with no statistically significant difference between the two groups ($P < 0.076$). The staining intensity of mast cells (CD117) in the periapical cysts was predominantly of severe type (58.8%), while in periapical granulomas it was predominantly of moderate type (44.4), with no statistically significant difference ($P = 0.411$) (Table 1).

5. Discussion

The inflammatory infiltrate of periapical lesions consists of plasma cells, lymphocytes and macrophages (6). The role of mast cells in allergy and the innate immune response has been well elucidated; however, their involvement in the pathogenesis of periapical lesions has not been well understood and, in most cases, they are attributed to hypersensitivity reactions (6). Basophils can release tryptase like mast cells. Therefore, in the present study, we used the CD117 staining technique, because it has a higher sensitivity to identify mast cells and to differentiate them from basophils (6).

In the present study, mast cells were identified in all evaluated samples (periapical granuloma and the connective chorion of periapical cysts), which is comparable with the studies by Drazic et al. and Rodini et al. in which mast cells were observed in all areas of periapical cysts and granulomas (6, 7). One of the first and pioneering studies on this aspect was performed by Matheisen et al.

who showed the presence of mast cells in periapical cysts and granulomas (14). In various studies, mast cells have been observed and reported in different areas (9). Several researchers have reported the presence of mast cells predominantly in inflamed areas and several others in vascular and fibrotic areas, while the rest in subepithelium of odontogenic cysts, which shows the role of mast cells in the initiation, development and progression of these lesions through vasodilation, production of proteoglycans, allergic responses, synthesis of collagen, regulation of inflammation, bone resorption and destruction of extracellular matrix (9, 15-18). In a study by Drazic et al. mast cells were not observed in all samples, but they were found in the majority (71%) of periapical lesions (6), demonstrating the great importance of mast cells in the pathogenesis of these lesions.

The results of the present study showed higher mast cell counts in periapical granulomas compared to periapical cysts, with no statistically significant difference. In the study by Drazic et al. on periapical cysts and granulomas using the C-KIT marker, higher mast cell counts were found in periapical cysts compared to periapical granulomas, with statistically significant difference (6), which is contrary to our study. In a study by Rodini et al. the presence of mast cells in periapical cysts and granulomas was evaluated using tryptase marker. Their results showed higher mast cell counts in periapical cysts compared to periapical granulomas, with a statistically significant dif-

ference (7), which is not in concordance with our study. The differences might be attributed to a variation in the type of markers used for evaluation of mast cells.

Ledesma-Montes et al. have used the toluidine blue staining technique and reported a higher mast cell count in periapical granulomas compared to periapical cysts (9). We used CD117 to stain mast cells and observed intense staining in periapical cysts and moderate staining in periapical granulomas, with half of the total samples having intense staining and almost one-third showing moderate staining, which is considered a higher staining intensity compared to Drazic et al. study, in which 15% and 8% had moderate and intense staining, respectively (6). The differences might be related to various staining techniques. However, no statistically significant difference was observed in staining intensity between periapical cysts and granulomas in the latter study, similarly to ours.

Although our study was unable to find a relation between mast cell count and periapical cysts and granulomas, studies revealed that mast cells participate in the pathogenesis of this disease by increasing cysts size through the release of heparin and other hydrolytic enzymes, which can degrade glycosaminoglycans and proteoglycans in the cystic fluid and increase the osmotic and hydrostatic pressure within the cyst (17). Smith and colleagues reported that mast cells population is high in odontogenic cysts, as a source of mucopolysaccharides, which promote the development of these lesions (19). Additionally, Teronen et al. reported that the presence of degranulated mast cells in odontogenic cysts and in the immediate vicinity of the surrounding bone is responsible for bone resorption and enlargement of the cyst (20). Multiple studies have stressed the role of mast cells in bone loss and the pathogenesis of osteoporosis. De Noronha Santos Netto et al. suggested that mast cells could regulate the activity of osteoclasts by releasing granules containing stem cell factor (17). Drazic et al. reported that mast cells are responsible for an increase in bone loss by releasing heparin and tumor necrosis factor alpha (TNF- α), which are osteoclast activators (6).

In our study, mast cells were identified in all samples; hence, they probably play a critical role in bone loss in periapical lesions. Mast cells release tryptase, kinase, and cytokines, including TNF- α and (interleukin 1) IL-1, which degrade connective tissue by activation of matrix metalloproteinases (9). Interestingly, mast cells are the only cells which release TNF- α from pre-synthesized pools in 10-20 minutes after activation (7). Since the presence of TNF- α has been reported in human periapical lesions (7), the effects of this proinflammatory cytokine include osteoclastic bone loss (6, 7, 17), an increase in local vascular response and progression of chronic inflammation (7).

Although the previous studies have shown the role of mast cells in the angiogenesis of various lesions, a very small number of studies have evaluated the possible role of mast cells in the angiogenesis of periapical le-

sions. Lima et al. showed the presence of mast cells in all periapical cysts and granuloma samples and reported a positive relationship between tryptase-positive mast cells and angiogenesis (21). Sabarinath et al. reported a relationship between angiogenesis and the number of tryptase-positive mast cells in submucous fibrosis of the oral cavity and considered that it was an important factor in the pathogenesis of the lesion (22). Murata et al. mentioned that mast cells have the greatest role in the neovascularization of the fleshy tissue bud (23). Walsh demonstrated an association between the density of mast cells in tissue components and expression of E-selectin, which is an endothelial adhesion molecule with the ability to activate and induce mast cell degranulation with TNF- α granules (24).

The task of mast cells in IgE-dependent hypersensitivity reactions is well-established. In this regard, Perrini et al. reported hypersensitivity in periapical granuloma and linked it to degranulation of mast cells, because the lesions contained IgE (25). Torabinejad and Bakland reported in their study that mast cells and plasma cells are present in periapical granulomas and contain IgE (26). Moreover, it has been established that mast cells form fibrotic tissues by producing hyaluronic acid. In addition, the aggregation of mast cell results in maturation of collagen fibers by releasing heparin. On the other hand, it has been shown that mast cells activate fibroblasts and induce synthesis of collagen RNA by releasing tryptase (6).

Several studies have shown the role of mast cells in inducing fibrotic tissues in inflammatory lesions of the kidneys, lungs and the oral cavity (27). Based on our results, mast cells exist in both periapical cysts and granulomas; hence, it may be concluded that fibrotic complications in periapical cysts and granulomas are related to mast cells functions. However, further studies are necessary to evaluate the relationship between periapical cysts and granulomas pathogenesis and mast cell counts.

Acknowledgements

This manuscript is based on a thesis (Thesis number: 581) submitted to the graduate faculty, Faculty of Dentistry, Hamadan University of Medical Sciences, Hamadan, Iran, in partial fulfillment of the requirements for the D.D.S degree.

References

1. White SC, Pharoah MJ. *Oral radiology principles and interpretation*. 6th ed Toronto, Ontario: Mosby Elsevier; 2009.
2. Regezi JA, Sciubba JJ, Jordan RCK. *Oral pathology Clinical Pathologic Correlation*. 5th ed Philadelphia: W B Saunders Co; 2008.
3. Fernandes M, de Ataíde I. Nonsurgical management of periapical lesions. *J Conserv Dent*. 2010;**13**(4):240-5.
4. Neville BW, Damm DD, Allen CM, Bouquot JE. *Maxillofacial Pathology*. 3rd ed China: Saunders Elsevier; 2009.
5. Liapatas S, Nakou M, Rontogianni D. Inflammatory infiltrate of chronic periradicular lesions: an immunohistochemical study. *Int Endod J*. 2003;**36**(7):464-71.
6. Drazic R, Sopta J, Minic AJ. Mast cells in periapical lesions: potential role in their pathogenesis. *J Oral Pathol Med*. 2010;**39**(3):257-62.

7. Rodini CO, Batista AC, Lara VS. Comparative immunohistochemical study of the presence of mast cells in apical granulomas and periapical cysts: possible role of mast cells in the course of human periapical lesions. *Oral Surg Oral Med O.* 2004;**97**(1):59-63.
8. Colic M, Gazivoda D, Vucevic D, Vasilijic S, Rudolf R, Lukic A. Pro-inflammatory and immunoregulatory mechanisms in periapical lesions. *Mol Immunol.* 2009;**47**(1):101-13.
9. Ledesma-Montes C, Garces-Ortiz M, Rosales-Garcia G, Hernandez-Guerrero JC. Importance of mast cells in human periapical inflammatory lesions. *J Endod.* 2004;**30**(12):855-9.
10. Dirnhofer S, Zimpfer A, Went P. [The diagnostic and predictive role of kit (CD117)]. *Ther Umsch.* 2006;**63**(4):273-8.
11. Rosai J. *Ackerman's Surgical pathology.* 9th edEdinburgh London: Mosby Co; 2004.
12. Minnei F, Wetzels C, De Hertogh G, Van Eyken P, Ectors N, Ambu R, et al. Chronic urticaria is associated with mast cell infiltration in the gastroduodenal mucosa. *Virchows Arch.* 2006;**448**(3):262-8.
13. Leon A, Ceausu Z, Ceausu M, Ardeleanu C, Mehedinti R. Mast cells and dendritic cells in basal cell carcinoma. *Rom J Morphol Embryol.* 2009;**50**(1):85-90.
14. Matheisen A. Preservation and demonstration of mast cells in human apical granulomas and radicular cysts. *Scand J Dental Res.* 1973;**81**:218-29.
15. Kabashima H, Nagata K, Maeda K, Iijima T. Involvement of substance P, mast cells, TNF-alpha and ICAM-1 in the infiltration of inflammatory cells in human periapical granulomas. *J Oral Pathol Med.* 2002;**31**(3):175-80.
16. Piattelli A, Artese L, Rosini S, Quaranta M, Musiani P. Immune cells in periapical granuloma: morphological and immunohistochemical characterization. *J Endod.* 1991;**17**(1):26-9.
17. de Noronha Santos Netto J, Pires FR, da Fonseca EC, Silva LE, de Queiroz Chaves Lourenco S. Evaluation of mast cells in periapical cysts, dentigerous cysts, and keratocystic odontogenic tumors. *J Oral Pathol Med.* 2012;**41**(8):630-6.
18. Patidar KA, Parwani RN, Wanjari SP, Patidar AP. Mast cells in human odontogenic cysts. *Biotech Histochem.* 2012;**87**(6):397-402.
19. Smith G, Smith AJ, Basu MK. Mast cells in human odontogenic cysts. *J Oral Pathol Med.* 1989;**18**(5):274-8.
20. Teronen O, Hietanen J, Lindqvist C, Salo T, Sorsa T, Eklund KK, et al. Mast cell-derived tryptase in odontogenic cysts. *J Oral Pathol Med.* 1996;**25**(7):376-81.
21. Lima SC, Rizo VH, Silva-Sousa YT, Almeida LY, Almeida OP, Leon JE. Immunohistochemical evaluation of angiogenesis and tryptase-positive mast cell infiltration in periapical lesions. *J Endod.* 2011;**37**(12):1642-6.
22. Sabarinath B, Sriram G, Saraswathi TR, Sivapathasundharam B. Immunohistochemical evaluation of mast cells and vascular endothelial proliferation in oral submucous fibrosis. *Indian J Dent Res.* 2011;**22**(1):116-21.
23. Murata M, Hara K, Saku T. Dynamic distribution of basic fibroblast growth factor during epulis formation: an immunohistochemical study in an enhanced healing process of the gingiva. *J Oral Pathol Med.* 1997;**26**(5):224-32.
24. Walsh LJ, Davis MF, Xu LJ, Savage NW. Relationship between mast cell degranulation and inflammation in the oral cavity. *J Oral Pathol Med.* 1995;**24**(6):266-72.
25. Perrini N, Fonzi L. Mast cells in human periapical lesions: ultrastructural aspects and their possible physiopathological implications. *J Endod.* 1985;**11**(5):197-202.
26. Torabinejad M, Bakland LK. Immunopathogenesis of chronic periapical lesions. A review. *Oral Surg Oral Med Oral Pathol.* 1978;**46**(5):685-99.
27. Kondo S, Kagami S, Kido H, Strutz F, Muller GA, Kuroda Y. Role of mast cell tryptase in renal interstitial fibrosis. *J Am Soc Nephrol.* 2001;**12**(8):1668-76.