



# A Maxillary Third Molar With 2 Distobuccal Canals: A Case Report

Zakiyeh Donyavi<sup>1</sup>, Mohammad Esmaeilzadeh<sup>2</sup>, Najme Kermani<sup>1\*</sup>

## Abstract

**Introduction:** Knowledge about the anatomy and morphology of the root canal system plays an important role in the prognosis of endodontic treatment and its success. Maxillary third molars with two distobuccal canals have been rarely reported. Herein, we report a maxillary third molar with 2 canals in the distobuccal root and describe its successful endodontic treatment.

**Case Presentation:** Our patient was a 67-year-old man referred to a private endodontic clinic complaining of pain in his maxillary right third molar tooth. With the diagnosis of irreversible pulpitis, the tooth underwent root canal therapy, during which, after thorough negotiation of orifices, a second distobuccal canal was found. Cleaning and shaping were carried out and root canals were filled. A follow-up was scheduled to ensure a successful endodontic treatment.

**Conclusions:** In this case, we did not use any adjunct diagnostic modality. We only found an additional canal by extending the access cavity and paying attention to landmarks by probing the fissures and grooves between the main orifices. However, it seems that use of new methods can enhance a successful treatment especially in the elderly patients.

## \*Correspondence to

Najme Kermani, Department of Endodontics, Hamadan University of Medical Sciences, Hamadan, Iran.  
Tel: 081-38324240,  
Fax: 021-26109848  
Email: drnajmekermani@gmail.com

**Keywords:** Maxilla, Molar, Root canal therapy, Third

**Received** December 8, 2017

**Accepted** January 20, 2018

**Published** March 3, 2018

Citation: Donyavi Z, Esmaeilzadeh M, Kermani N. A maxillary third molar with 2 distobuccal canals: a case report. Avicenna J Dent Res. 2018;10(1):28-30. doi: 10.15171/ajdr.2018.06.



## Introduction

The main goal of endodontic treatment is to completely remove the microorganisms and debris from the root canal system followed by cleaning and shaping of the root canals by appropriate instruments and irrigants and efficient techniques.

On the other hand, Knowledge about the anatomy and morphology of root canal system is an important factor in determining the prognosis of endodontic treatment. Adequate knowledge, precision of work and patience to find the canals are all important in this respect.

The morphology of the root canal system is variable. A number of factors that could affect the root canal morphology include: ethnic background (1), age of patient, and gender (2). There are case reports, describing teeth with four (3), five (4), six (5), seven (6) and eight (7) canals. C-shaped configuration of the canals has also been reported. Ghoddusi et al (8) reported a maxillary first molar tooth with five canals including one palatal, 2 mesiobuccal, and 2 distobuccal root canals.

Martinez-Berna and Ruiz Baddanelli (9) described a maxillary first molar with 6 canals including 3 mesiobuccal canals, 2 distobuccal canals, and 1 palatal canal. Kumar (10) reported a maxillary first molar with three separate roots and seven canals namely three mesiobuccal, 2 distobuccal, and 3 palatal canals. Alavi et al (11) reported that the incidence of 2 distobuccal roots

## Highlights

It seems that use of new methods for treatment of maxillary third molar with 2 canals in the distobuccal root can enhance a successful treatment especially in the elderly patients.

was 1.90%; whereas, in a report by Thomas et al (12), the incidence of double canals in distobuccal roots was 4.30%. Malagnino et al (13) in 1997 stated that maxillary third molars could have omnifarious root forms that included three fused roots (37%), 2 fused roots (7%), 4 fused roots (2%), and 4 separate roots (<2%).

Sidow et al (14) in 2000 evaluated the number of maxillary third molar roots and reported the prevalence of only 1 root to be 15%, 2 roots to be 32%, 3 roots to be 45%, and 4 roots to be 7%. The number of canals varied from 1 to 6 in one root, 3 to 5 in double rooted teeth, 2 to 5 in three rooted teeth, and 4 to 5 canals in teeth with four roots.

There are many different ways to define the position of the canals. Pomeranz and Fishelberg (15) described the importance of extension of the access cavity and probing the fissures and grooves between major canals to scrutinize the accurate morphology of the pulp chamber. The advent of dental operative microscope significantly enhanced finding extra canals in endodontic treatment.

Herein, we report a maxillary third molar with 2

<sup>1</sup>Department of Endodontics, Hamadan University of Medical Sciences, Hamadan, Iran. <sup>2</sup>Pediatric Dentistry Department, Hamadan University of Medical Sciences, Hamadan, Iran.

canals in the distobuccal root and describe its successful endodontic treatment.

### Case Presentation

Our patient was a 67-year-old man referred to a private endodontic clinic in Hamadan. His chief complaint was pain in his maxillary right third molar tooth. The tooth #1 was abutment tooth with a short-span bridge and was not endodontically treated (Figures 1 and 2). The bridge was removed and the patient was referred with his radiograph ordered by his previous dentist.

Vitality tests revealed that tooth #1 had irreversible pulpitis. Periradicular tissues did not have any problem. His medical history was unremarkable. The tooth had physiologic mobility and probing depth was less than 3 mm. Periodontal prognosis was good.

First, local anesthesia (lidocaine with 1:100 000 epinephrine) was injected and then a rubber dam was placed and access cavity was prepared. After negotiation of the major orifices (palatal, first mesiobuccal, distobuccal) and considering the fact that we have to consider the presence of second mesiobuccal canal in all maxillary molars, we proceeded to find the second mesiobuccal canal in the expected area between the first mesiobuccal and palatal canals, however despite the attention to anatomical landmarks and after following the groove between the first mesiobuccal and palatal orifices, the second mesiobuccal canal was not found. With further negotiation of the pulp chamber floor, another orifice was found in the distal area.

A #8 K file (Dentsply Maillefer, Ballaigues, Switzerland)

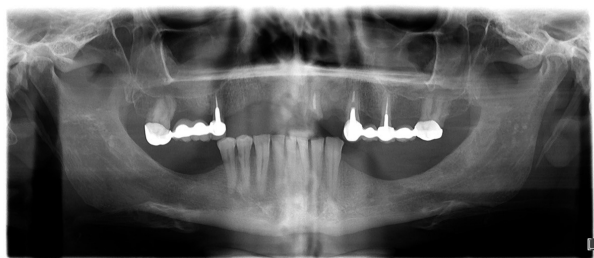

Figure 1. Panoramic Radiograph of the Patient

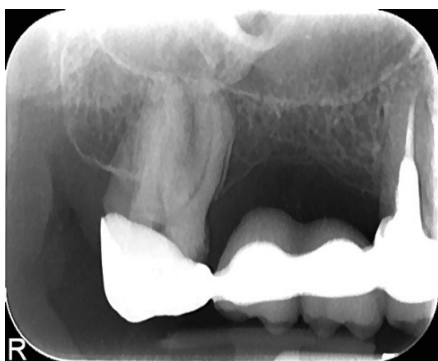

Figure 2. Short-span Bridge.

was introduced into the canal and a radiograph was obtained, which revealed that the orifice probably belonged to the second distobuccal canal.

Then, #10 and 15 (Dentsply Maillefer, Ballaigues, Switzerland) initial files were placed in the canals and using an apex locator (J Morita, USA), we determined the working length and radiographically confirmed it (Figure 3).

Instrumentation was completed using MTWO (VDW GmbH, Munchen, Germany) rotary system (#30, 0.06 for palatal canal and #25, 0.07 for mesiobuccal and distobuccal canals), standard technique and Rc-Prep (Premier Dental Products, USA) as a chelating agent with 5.25 % sodium hypochlorite irrigant.

After cleaning and shaping, the root canals were filled with gutta-percha (Gapadent, Korea) and AH26 sealer (Detroy, Dentsply, USA) using lateral compaction technique.

The patient was referred for the restoration and the tooth was restored with composite resin.

The post-operative radiograph showed that the additional canal was near the first distobuccal canal (major distobuccal canal), thus, it was considered as the second distobuccal canal (Figure 4A and 4B).

Clinical and radiographic follow-ups were scheduled for the patient to ensure a successful endodontic treatment.

### Discussion

Appropriate endodontic treatment in molars with extra canals is important to ensure favorable prognosis of root canal therapy. Inability to find the extra canal and perform suitable treatment may lead to failure.

We reported a maxillary third molar tooth with an additional canal. Use of new methods such as ultrasound and spiral computed tomography (16), cone beam computed tomography (6) and dental operative microscope (10) can help clinicians to identify the accurate morphology of canals and pulp chamber to perform a successful endodontic treatment.

In this case, none of the new methods were used. We only found the additional canal by extending the access cavity and paying attention to landmarks by probing the

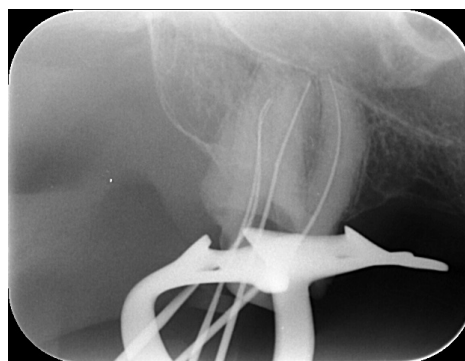
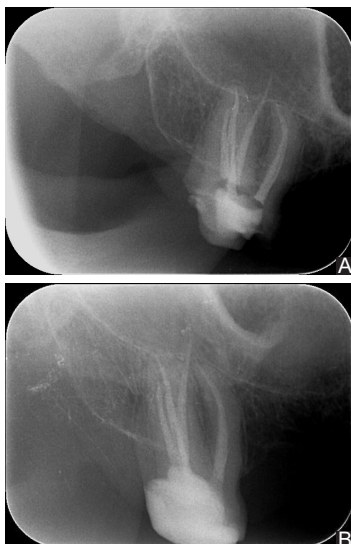

Figure 3. Working Length Radiography



**Figure 4.** (A) Final Radiography and (B) Radiograph After 6 Months.

fissures and grooves between the main orifices. However, it seems that use of new methods can enhance a successful treatment especially in the elderly patients.

#### Authors' Contribution

Study concept, design and acquisition of data: ZD, NK; analysis, interpretation of data and drafting of the manuscript: ZD, ME, NK; critical revision of the manuscript for important intellectual content: ZD, ME, NK.

#### Ethical Statement

This article was performed as under graduated thesis and approved by Deputy of research and technology.

#### Conflict of Interest Disclosures

The authors declare that they have no conflict of interests.

#### References

1. Sert S, Bayirli GS. Evaluation of the Root Canal Configurations of the Mandibular and Maxillary Permanent Teeth by Gender in the Turkish Population. *J Endod.* 2004;30(6):391-8. doi: [10.1097/00004770-200406000-00004](https://doi.org/10.1097/00004770-200406000-00004).
2. Wong M. Maxillary first molar with three palatal canals. *J Endod.* 1991;17(6):298-9. doi: [10.1016/s0099-2399\(06\)81871-6](https://doi.org/10.1016/s0099-2399(06)81871-6).
3. Christie WH, Peikoff MD, Fogel HM. Maxillary molars with two palatal roots: a retrospective clinical study. *J Endod.* 1991;17(2):80-4. doi: [10.1016/s0099-2399\(06\)81613-4](https://doi.org/10.1016/s0099-2399(06)81613-4).
4. Barbizam JV, Ribeiro RG, Tanomaru Filho M. Unusual anatomy of permanent maxillary molars. *J Endod.* 2004;30(9):668-71.
5. Bond JL, Hartwell G, Portell FR. Maxillary first molar with six canals. *J Endod.* 1988;14(5):258-60. doi: [10.1016/S0099-2399\(88\)80180-8](https://doi.org/10.1016/S0099-2399(88)80180-8).
6. Badole GP, Warhadpande MM, Sheno PR, Lachure C, Badole SG. A rare root canal configuration of bilateral maxillary first molar with 7 root canals diagnosed using cone-beam computed tomographic scanning: a case report. *J Endod.* 2014;40(2):296-301. doi: [10.1016/j.joen.2013.09.004](https://doi.org/10.1016/j.joen.2013.09.004).
7. Kottoor J, Velmurugan N, Surendran S. Endodontic management of a maxillary first molar with eight root canal systems evaluated using cone-beam computed tomography scanning: a case report. *J Endod.* 2011;37(5):715-9. doi: [10.1016/j.joen.2011.01.008](https://doi.org/10.1016/j.joen.2011.01.008).
8. Ghoddsi J, Javidi M, Vatanpour M. Two symmetrical maxillary first molars with two disto-buccal root canals. *Iran Endod J.* 2006;1(2):73-7.
9. Martinez-Berna A, Ruiz-Badanelli P. Maxillary first molars with six canals. *J Endod.* 1983;9(9):375-81. doi: [10.1016/S0099-2399\(83\)80188-5](https://doi.org/10.1016/S0099-2399(83)80188-5).
10. Kumar R. Report of a rare case: a maxillary first molar with seven canals confirmed with cone-beam computed tomography. *Iran Endod J.* 2014;9(2):153-7.
11. Alavi AM, Opananon A, Ng YL, Gulabivala K. Root and canal morphology of Thai maxillary molars. *Int Endod J.* 2002;35(5):478-85.
12. Thomas RP, Moule AJ, Bryant R. Root canal morphology of maxillary permanent first molar teeth at various ages. *Int Endod J.* 1993;26(5):257-67.
13. Malagnino V, Gallottini L, Passariello P. Some unusual clinical cases on root anatomy of permanent maxillary molars. *J Endod.* 1997;23(2):127-8. doi: [10.1016/s0099-2399\(97\)80260-9](https://doi.org/10.1016/s0099-2399(97)80260-9).
14. Sidow SJ, West LA, Liewehr FR, Loushine RJ. Root canal morphology of human maxillary and mandibular third molars. *J Endod.* 2000;26(11):675-8. doi: [10.1097/00004770-200011000-00011](https://doi.org/10.1097/00004770-200011000-00011).
15. Pomeranz HH, Fishelberg G. The secondary mesiobuccal canal of maxillary molars. *J Am Dent Assoc.* 1974;88(1):119-24.
16. Sharma R, Maroli K, Sinha N, Singh B. An unusual maxillary molar with four roots and four buccal canals confirmed with the aid of spiral computed tomography: a case report. *J Int Oral Health.* 2014;6(4):80-4.