



# A Case Report of a Tongue Ulcer as a Rare Presentation of Oral Hemangioma

Narges Rozebahani<sup>1</sup>, Shokofeh Jamshidi<sup>2</sup>, Lida Samie<sup>3</sup>, Fatemeh Ahmadi-Motamayel<sup>4\*</sup>**Abstract**

Oral hemangioma is a rare benign vascular tumor. It may occur on lips, tongue, buccal mucosa, and palate. Hemangioma is a congenital hamartoma and its clinical presentations and patients' history aid in its diagnosis. Histopathologically, hemangioma shows flatted endothelial cells and small capillary size space. In this report, we will describe a rare presentation of oral hemangioma as an asymptomatic tongue ulcer in a 32-year-old woman. The clinical presentation, differential diagnosis, and management will also be described in detail.

**\*Correspondence to**

Fatemeh Ahmadi-Motamayel,  
Tel: +98-81-38381059  
Fax: +98-81-38381085  
Email: f.ahmadi@umsha.ac.ir

**Keywords:** Hemangioma,  
Oral, Ulcer

**Received** Sep. 27, 2018

**Accepted** Dec. 14, 2018

**ePublished** Dec. 27, 2018

Citation: E. A case report of a tongue ulcer as a rare presentation of oral hemangioma. Avicenna J Dent Res. 2018;10(4):148-150. doi: 10.34172/ajdr.2018.29.

**Background**

Vascular anomalies include a wide range of tumors and malformations (1). Among vascular anomalies, hemangioma is most frequently detected in the head and neck regions (1-3). Hemangioma often refers to congenital hamartomas and vascular disorders. Overall, it is considered as a developmental disorder, which is often identified in the early stages (3).

Hemangioma is regarded as the most common type of tumor among children so that it is reported in nearly 5%-10% of children below one year. It is characterized by fast development, proliferation of endothelial cells, and progressive involution (4). In most cases of hemangioma, the head and neck regions are affected, whereas the oral cavity is an uncommon site of occurrence. They may occur at any site or at any age without any variations among different races or genders (3). Hemangioma in the oral region mostly affects the lips, tongue, and buccal mucosa, while the hard and soft palates normally remain unaffected (2, 3).

Clinically, hemangioma appears as a soft, smooth or lobulated mass. It is a sessile or pedunculated lesion, which can lead to the formation of ulcers, pain, bleeding, secondary infections, and tissue abnormalities (2, 5). Lesions vary in size from a few millimeters to several centimeters (4). Histopathologically, hemangioma shows flatted endothelial cells and small capillary size space (4). In this report, we will describe an unusual case of capillary hemangioma of the tongue.

**Case Report**

Herein, we will report a female case (32 years old)

**Highlights**

- ▶ Tongue ulcer is very important in according to high risk area in the oral cavity.
- ▶ Clinicians should aware and be careful in clinical examination and oral lesions biopsy.

complaining of an ulcer on the middle third of the left lateral border of the tongue. The size of the ulcer had not changed since 2 months ago. The ulcer was asymptomatic but began to develop with pain. The patient had no systemic disease and no history of foreign body reaction or trauma.

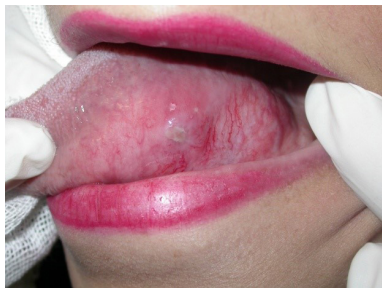Intraoral examination revealed a solitary aphthous-like ulcer with a well-defined and indurated border without erythematous border. The ulcer located on the middle-third left lateral surface of the tongue and was measured at approximately 0.5 cm × 0.5 cm.

The surrounding tissues of the ulcer were hypervascular and hypertrophic compared to the right side of the tongue (Figure 1). There were no palpable lymph nodes in the face and neck regions.

According to the clinical signs and symptoms, orofacial granulomatosis, foreign body granulomatosis reaction, and eosinophilic ulcer of the tongue were considered in the differential diagnosis.

Excisional biopsy and histopathological assessment were applied for diagnosis given the relatively small size of the lesion. In the surgery procedure we observed gross and jetting bleeding that interfered with the procedure. The tongue bleeding during biopsy was controlled with electrocautery. The microscopic examination of

<sup>1</sup>Associate Professor of Oral Medicine, Khoramabad University of Medical Sciences, Lorestan, Iran. <sup>2</sup>Associate Professor, Dental Research Center, Department of Oral and Maxillofacial Pathology, School of Dentistry, Hamadan University of Medical Sciences, Hamadan, Iran. <sup>3</sup>Assistant Professor, Department of Oral Medicine, School of Dentistry, Hamadan University of Medical Sciences, Hamadan, Iran. <sup>4</sup>Associate Professor, Dental Research Center and Research Center for Molecular Medicine, Department of Oral Medicine, Hamadan University of Medical Sciences, Hamadan, Iran.



**Figure 1.** A Small Aphthous Like Ulcer in Left Lateral Border of Tongue.

the specimens revealed a vascular tumor with lobular architecture. Connective tissue showed numerous capillary-sized vessels lined by plump endothelial cells extending between skeletal muscles (Figures 2 and 3). Some of the vessels were filled with RBCs. The lesion was covered by parakeratinized stratified squamous epithelium with acanthosis. Therefore, given the clinical and histological results, the patient was diagnosed with capillary hemangioma. This patient did not attend for follow-up examinations after the confirmation of the diagnosis.

### Discussion

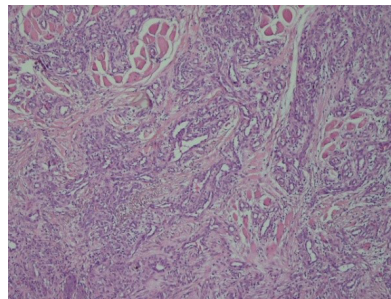
Hemangiomas are common developmental vascular abnormalities, with head and neck regions, mainly face, lips and oral mucosa, commonly involved, but the tongue is rarely involved as in our case report. The term “hemangioma” may be misused for various vasculoformative tumors (1).

Today, hemangiomas and vascular malformations include vasoformative tumors. Hemangioma is regarded as a benign tumor of endothelial cells and is of two types, ie, capillary and cavernous hemangioma. Capillary hemangioma includes an abnormal overgrowth of tiny blood vessels (1,6).

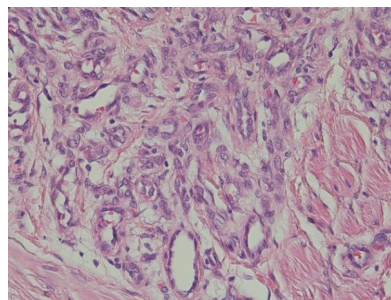
Capillary hemangioma may be immobile or pedunculated. It is a soft, smooth, or irregular tumor, which is round and swollen in the outlines; it is also pain-free if not exacerbated (3). The syndromes associated with hemangioma include Osler-Weber-Rendu syndrome, Sturge-Weber syndrome, and blue rubber bleb syndrome (1,7).

Differential diagnosis in our case could be orofacial granulomatosis, foreign body granulomatosis reaction and eosinophilic ulcer of the tongue. However, the lesion has microscopic appearance of capillary hemangioma. Hemangioma of the tongue needs special attention due to susceptibility to trauma from masticatory forces leading to difficulty breathing and dysphagia (1,8).

Hemangioma treatment is dependent on several factors, including the patient’s age and the size and clinical features of the lesion. As observed in the present case, lesions that are smaller in size can be successfully removed (3). Other treatment strategies for benign vascular lesions include



**Figure 2.** A Microscopic feature showed lobules of tumor cells extending between skeletal muscles (hematoxylin-eosin, 100x)



**Figure 3.** Microscopic feature revealed numerous capillary-sized vessels (hematoxylin-eosin, 400 x)

corticosteroids, interferon-alpha, embolization, laser therapy, cryosurgery, and radiotherapy (5,6,9).

Most cases of hemangioma can be clinically identified. In fact, no assessment or treatment is required because these tumors spontaneously recede (10).

### Conclusions

In cases similar to our reported one, histopathological diagnosis and selection of an appropriate treatment method are essential because it is difficult to make a definite diagnosis in cases of intraoral ulcer.

### Authors’ Contribution

NR, LS and FAM: article preparation, patients clinical examination biopsy and follow up. SJ: histo-pathologic examination.

### Conflict of Interest Disclosures

All authors declare that there is no conflict of interests.

### Ethical Statement

Informed consent was obtained from the patient for the publication of this report.

### References

1. Khanduri S, Agrawal D, Varshney G, Singh N. Haemangioma of tongue: A rare case report. *Journal of Oral and Maxillofacial Radiology*. 2015;3(1):25. doi: [10.4103/2321-3841.151645](https://doi.org/10.4103/2321-3841.151645).
2. Gill JS, Gill S, Bhardwaj A, Grover HS. Oral haemangioma. *Case Rep Med*. 2012;2012:347939. doi: [10.1155/2012/347939](https://doi.org/10.1155/2012/347939).
3. Singh P, Parihar AS, Siddique SN, Khare P. Capillary haemangioma on the palate: a diagnostic conundrum. *BMJ Case Rep*. 2016;2016:bcr2015210948. doi: [10.1136/bcr-2015-210948](https://doi.org/10.1136/bcr-2015-210948).
4. Neville BW, Damm DD, Allen CM, Bouquot JE. *Oral &*

- Maxillofacial Pathology. 3th ed. Philadelphia: Saunders; 2009. p. 541-2.
5. Johann AC, Aguiar MC, do Carmo MA, Gomez RS, Castro WH, Mesquita RA. Sclerotherapy of benign oral vascular lesion with ethanolamine oleate: an open clinical trial with 30 lesions. *Oral Surg Oral Med Oral Pathol Oral Radiol Endod.* 2005;100(5):579-84. doi: 10.1016/j.tripleo.2004.12.021.
  6. Werner JA, Dünne A-A, Folz B, Rochels R, Bien S, Ramaswamy A, et al. Current concepts in the classification, diagnosis and treatment of hemangiomas and vascular malformations of the head and neck. *Eur Arch Otorhinolaryngol.* 2001;258(3):141-9.
  7. Kripal K, Rajan S, Ropak B, Jayanti I. Cavernous hemangioma of the tongue. *Case Rep Dent.* 2013;2013:898692. doi: [10.1155/2013/898692](https://doi.org/10.1155/2013/898692).
  8. Panta P. A purple swelling on the tongue. *Pan Afr Med J.* 2015;21:234. doi: [10.11604/pamj.2015.21.234.7497](https://doi.org/10.11604/pamj.2015.21.234.7497).
  9. Kamala K, Ashok L, Sujatha G. Cavernous hemangioma of the tongue: a rare case report. *Contemp Clin Dent.* 2014;5(1):95. doi: [10.4103/0976-237X.128680](https://doi.org/10.4103/0976-237X.128680).
  10. Nayak SK, Nayak P. Intramuscular hemangioma of the oral cavity—a case report. *J Clin Diagn Res.* 2014;8(8):ZD41-2. doi: [10.7860/JCDR/2014/8305.4756](https://doi.org/10.7860/JCDR/2014/8305.4756).

© 2018 The Author(s); Published by Hamadan University of Medical Sciences. This is an open-access article distributed under the terms of the Creative Commons Attribution License (<http://creativecommons.org/licenses/by/4.0>), which permits unrestricted use, distribution, and reproduction in any medium, provided the original work is properly cited.