

Assessment of Changes in the Hyoid Bone Position Following Orthognathic Surgery in Class III Patients

Shahin Setoudehmaram,¹ Sara Masoumi,^{2,*} Shahla Momeni Danaei,¹ and Barbod Zamiri³

¹Orthodontic Research Center, School of Dentistry, Shiraz University of Medical Sciences, Shiraz, IR Iran

²Department of Periodontology, School of Dentistry, Shiraz University of Medical Sciences, Shiraz, IR Iran

³Department of Oral and Maxillofacial Surgery, School of Dentistry, Shiraz University of Medical Sciences, Shiraz, IR Iran

*Corresponding author: S Masoumi, Dept. of Periodontology, School of Dentistry, Shiraz University of Medical Sciences, Shiraz, IR Iran. Tel: +98-9125213916, E-mail: masoumisa@sums.ac.ir

Received 2015 September 01; Revised 2016 August 15; Accepted 2016 October 10.

Abstract

Background: The hyoid bone position may change in class III patients following different surgical procedures, including mandibular setback, maxillary advancement, and bimaxillary advancement.

Objectives: The aim of this study was to conduct a detailed cephalometric evaluation of changes in the hyoid bone position following treatment of class III skeletal deformities via different surgical procedures (ie, mandibular setback, maxillary advancement, and bimaxillary advancement).

Methods: A total of 120 consecutive patients, who were diagnosed with skeletal class III deformities, were recruited in this study. All the patients were adults with complete growth and cephalograms taken at 1 month before operation (T1) and 1 to 9 months postoperation (T2) in the natural head position. The patients were divided into 3 groups according to the type of surgery: group 1, bimaxillary advancement; group 2, mandibular setback; and group 3, maxillary advancement. The hyoid bone position was evaluated at both T1 and T2 in each group. The results were compared using paired t test and one-way ANOVA.

Results: The hyoid bone position showed no significant changes in groups 1 and 3 ($P < 0.05$), whereas a significant difference was found both horizontally and vertically in group 2 ($P < 0.05$).

Conclusions: The hyoid bone position changed only after mandibular setback surgery; the bone was displaced downward and backward following mandibular retraction. On the other hand, neither bimaxillary nor maxillary advancement could change the hyoid bone position.

Keywords: Orthognathic Surgery, Class III Deformity, Hyoid Bone Position

1. Background

Combinations of maxillary hypoplasia (undergrowth) and mandibular hyperplasia (overgrowth) can cause class III skeletal problems. The majority of patients require orthognathic surgery for successful treatment. Both growth modification and dental camouflage are relatively challenging in orthodontic treatment. In fact, even modest deviations in class III problems are not acceptable, especially in women.

Patients with class III skeletal patterns, ie, those with reverse overjet of more than 2 mm, usually require surgery, besides orthodontic treatment. In a previous study, among patients undergoing surgery, 50% only had a history of maxillary advancement, while 50% had undergone mandibular setback. Overall, mandibular surgery is usually combined with maxillary surgery; therefore, in this study, bimaxillary surgery was applied in about 40% of the patients. On the other hand, less than 10% of the patients had only undergone mandibular surgery (1).

The hyoid bone is a distinct bone in the head and neck

region. It has no synovial articulation with circumjacent bones, while it is connected to the adjacent structures with ligaments and muscles. The movement of the hyoid bone mainly depends on the attached muscles, such as those attaching it to the tongue and mandible. This bone serves as an indicator of tongue size and position, as these structures are directly related to each other. Therefore, changes in the tongue position can be evaluated more accurately by measuring changes in the hyoid bone position.

Mandibular setback osteotomy alone causes changes in the position of the hyoid bone and tongue. In addition, these changes seem to significantly affect the oropharyngeal airway space (2, 3). In this regard, Hwang et al. (2010) showed significant differences in the horizontal position of the hyoid bone and tongue, as well as oropharyngeal size, following mandibular setback. The hyoid bone and tongue were repositioned anteriorly after surgery ($P < 0.01$), thereby increasing the dimensions of the oropharyngeal airspace ($P < 0.01$) (4).

Furthermore, Kitahara et al. (2010) evaluated patients undergoing mandibular setback osteotomy and showed

the upward and forward movements of the hyoid bone due to the upward movements of the lower border of posterior airway space (PAS) in the sagittal split ramus osteotomy group after surgery. In contrast, the anterior border of PAS and hyoid bone showed considerable backward movements in the group undergoing intraoral vertical ramus osteotomy (5).

Halise Aydemir et al. (2012) reported no significant differences in the position of the hyoid bone or craniocervical posture after surgical setback of the mandible (6). On the other hand, De Arruda Cabral et al. (2013) showed significant differences in the oropharyngeal size and horizontal position of the hyoid bone and tongue. The hyoid bone and tongue were repositioned anteriorly after chin surgery ($P < 0.01$), thereby increasing the dimensions of the oropharyngeal airspace ($P < 0.01$) (7).

Efendiyeva et al. (2014) showed the significant superior movement of the hyoid bone after bimaxillary surgery ($P < 0.05$) (8). Nevertheless, there is no consensus regarding the final position or direction of hyoid bone movements after different class III surgical procedures. Therefore, in this study, we aimed to elucidate the possible directions and extent of movements in the hyoid bone, and subsequently the tongue, after different viable surgical procedures in the patients.

2. Methods

This retrospective study was performed on 120 consecutive patients, who were diagnosed with class III skeletal deformities. All the included patients were adults with complete growth. The subjects included 41 male and 79 female patients with the average age of 23.4 years at the onset of treatment (range, 18 - 31 years). All the patients had undergone fixed orthodontic treatment with edgewise appliances both before and after surgical procedures for the correction of jaw deformities. The subjects were selected based on the medical records available at the orthodontic departments of Shiraz University of Medical Sciences and Shahid Beheshti University of Medical Sciences, as well as a private clinic in Shiraz.

The records of 120 patients were selected retrospectively, based on the availability of lateral cephalograms taken at 1 month before operation (T1) and 1 to 9 months postoperation (T2) in the natural head position; all the cephalograms included the second and fourth cervical vertebrae. At least a 1-month interval was required between surgery and acquisition of postsurgical cephalograms to minimize the effects of postoperative swelling and edema, which may adversely affect the airway dimensions.

In order to correct class III deformities, the patients underwent maxillary, mandibular, or maxillomandibu-

lar surgeries. All the patients with mandibular setback surgery had undergone bilateral sagittal split ramus osteotomy (BSSRO). The patients with maxillary advancement had received LeFort I advancement osteotomy without impaction. In addition, the patients with bimaxillary advancement had undergone combined LeFort I maxillary advancement osteotomy without impaction, as well as BSSRO for mandibular setback. Moreover, all the patients had rigid internal fixation with fixation screws and/or plates following either maxillary or mandibular osteotomy.

The exclusion criteria in this study were as follows: 1) history of trauma to the face and jaws; 2) completely normal dentition with no missing teeth, except those extracted for orthodontic purposes and third molars; 3) apparent facial asymmetry; 4) syndromes related to the orofacial region; 5) cleft lip and/or palate; 6) history of orthognathic or facial cosmetic procedures, such as mandibular inferior border osteotomy (genioplasty); and 7) history of adenoidectomy or tonsillectomy.

The data regarding the exclusion criteria were gathered from the patients' medical and dental histories, cephalograms (ie, lateral and posteroanterior views), and facial and intraoral images available in the files. The patients were divided into 3 groups according to the type of surgery: group 1, patients with combined maxillary advancement and mandibular setback; group 2, patients with mandibular setback osteotomy; and group 3, patients with maxillary advancement.

2.1. Lateral Cephalograms

The Proline 2002 CC/XC X-ray source (Planmeca OY, 00880 Helsinki, Finland) was used to acquire the cephalograms. The cephalograms were hand-traced on a matte acetate tracing paper (0.003-inch thick, 8 × 10 inches; Tru-vision, Ortho Technology Inc., Florida, USA; distributed by Emergo Europe, Molenstraat, Netherlands) with a 3H drawing pencil.

2.2. Skeletal Landmarks

Sella (S): The geometric center of the pituitary fossa (9)

Nasion (N): The most anterior point on the frontonasal suture in the midsagittal plane (9)

Point A: The most inferior point on the alveolar bone overlying the maxillary incisors (9)

Point B: The most posterior point in the concavity between the chin and mandibular alveolar bone (9)

Anterior nasal spine (ANS): The anterior tip of the sharp bony process of maxilla at the lower margin of the anterior nasal opening (9)

Posterior nasal spine (PNS): The posterior spine of the palatine bone, constituting the hard palate (9)

Menton (Me): The lowest point on the symphyseal shadow of the mandible on a lateral cephalogram (9)

Gonion (Go): A point on the curvature of mandible angle, located by bisecting the angle formed by lines tangent to the posterior ramus and the inferior border of the mandible (9)

Hyoidale (Hy): The most superior point on the anterior surface of the outline of the hyoid bone, assumed to lie in the median sagittal plane of the hyoid bone (10)

CV2 ip: The most posterior point on the inferior margin of the outline of the second cervical vertebra (10)

CV4 ip: The most posterior point on the inferior margin of the outline of the fourth cervical vertebra (10).

2.3. Soft Tissue Landmarks

V: The deepest point of vallecula on the anterior pharyngeal wall (11).

2.4. Reference Lines

Mandibular line (ML): The line passing through the points, gonion and menton (9)

Maxillary line (NL): The line passing through the points, ANS and PNS (also known as the palatal plane) (9)

Presellar anterior cranial base (NSL): The line passing through the points, sella and nasion (9)

VRL: The line drawn through the most anterior point of the second cervical vertebra (axis or C2) parallel to the edge of the cephalometric film (9)

HRL: The line drawn through the point sella at the right angle to the edge of the cephalometric film (9).

2.5. Dentoskeletal Measurements

To assess the hard tissue relationships and to compare pre- and posttreatment data, the following linear and angular measurements were taken:

SNA (degrees): The angle formed by the planes sella-nasion and nasion-point A

SNB (degrees): The angle formed by the planes sella-nasion and nasion-point B

ANB (degrees): The angle formed by the planes nasion-point A and nasion-point B

Overbite (mm): The vertical distance from the upper to the lower incisor tip

Overjet (mm): The horizontal distance from the upper to the lower incisor tip

Maxillary advancement (mm): The distance from point A to the vertical reference line

Mandibular setback (mm): The distance from point B to the vertical reference line

Hy-NSL (mm): The distance from hyoidale to the sella-nasion plane

Hy-NL (mm): The distance from hyoidale to the ANS-PNS plane

Hy-ML (mm): The distance from hyoidale to the gonion-menton plane

VRL-Hy (mm): The distance from hyoidale to the vertical reference line

Hy-CV2ip (mm): The distance from hyoidale to the second cervical vertebra

Hy-CV4ip (mm): The distance from hyoidale to the fourth cervical vertebra

Hy-V (mm): The distance from hyoidale to the deepest point of vallecula (Figure 1).

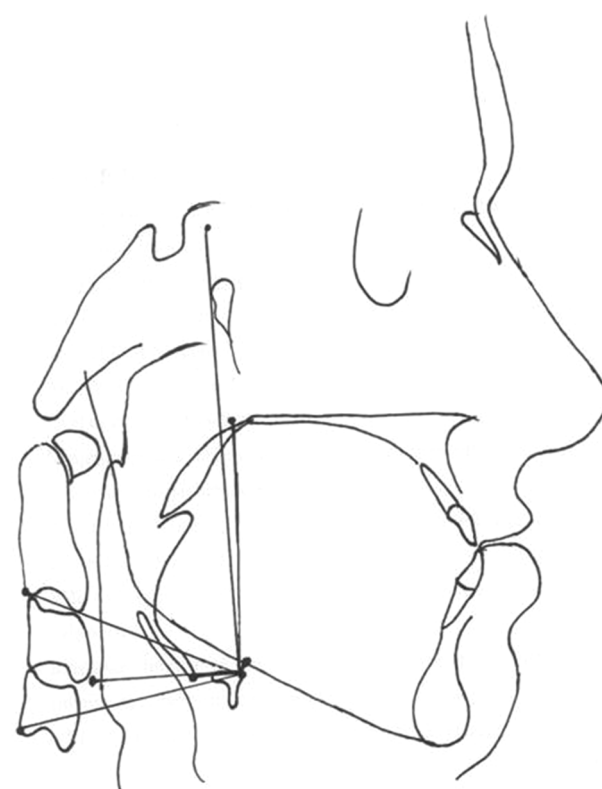


Figure 1. The hyoid bone measurements

2.6. Method Error

Each cephalogram was traced and measured manually by a single operator. Half of the cephalograms were randomly selected from each group after 2 weeks. All the measurements were repeated for each case. The differences between the original and retraced cephalograms were analyzed in the revised manuscript, using intraclass correlation coefficient (ICC). The ICC value (rICC, 0.899; $P < 0.001$) showed high reliability between the measurements.

Therefore, the original measurements, used for the analysis of the hyoid bone, were reliable.

2.7. Statistical Analysis

Data were gathered and analyzed using different statistical tests. The group characteristics were compared according to the type of surgery, using one-way ANOVA test (for the variable of age) and Chi square test (for the variable of sex). For the comparison of dependent variables (eg, CVT and SN; VRL and EP) before and after surgery, paired t test was performed. In addition, for comparing the mean differences of dependent variables between the groups, ANOVA test was applied.

The effects of groups on the mean differences of dependent variables were determined after adjustments for other independent variables (eg, age, sex, advancement, setback, and face height), using ANCOVA models. The independent variables, ie, advancement and setback, were not defined for all the groups (advancement, groups 1 and 3; setback, groups 1 and 2). Therefore, to evaluate the group effects on the mean differences of dependent variables, subjects from groups 1 and 3 were selected after adjustments for advancement and entered the multiple linear model. Moreover, subjects were selected from groups 1 and 2 after controlling for setback and entered the model.

In the multiple linear models, the variable of "group" was incorporated in the models with the "enter" method. Normal distribution of the data was assessed with Kolmogorov-Smirnov test, and the results showed that the data were normally distributed ($P > 0.05$). Moreover, box plots were used to visualize the results. The statistical tests were conducted with SPSS version 16 at a two-sided P value of < 0.05 .

3. Results

The demographic information of class III patients in groups I, II, and III are presented in [Table 1](#). The changes in the hyoid bone position in class III patients after surgical intervention are shown in [Table 2](#). As it can be seen, there were no positional changes in the hyoid bone in group I ($P > 0.05$). Both horizontal and vertical relationships of the hyoid bone to different planes and landmarks remained unchanged in cephalometrics, based on the comparison of pre- and postsurgical measurements. In addition, in each subgroup, the hyoid position measurements showed no significant differences in either female or male patients ($P > 0.05$; [Tables 3](#) and [4](#)).

In group II, there were significant differences in the hyoid bone position both horizontally and vertically ($P < 0.05$). The Hy-NSL, Hy-NSL, Hy-NL, and Hy-ML changes

showed downward movement of the hyoid bone after mandibular setback, while Hy-CV4ip and VRL-Hy changes revealed the backward movement of the hyoid bone after surgery. In each subgroup, the changes were completely similar to the overall changes in the mandibular setback group ($P < 0.05$). In neither the vertical nor the horizontal dimension in group III, the hyoid bone position showed significant changes after maxillary advancement ($P > 0.05$). Moreover, considering gender differences, there were no significant differences between male and female subjects ($P > 0.05$).

4. Discussion

According to the literature, changes in tongue position can be analyzed more precisely by measuring the changes in the hyoid bone position ([12](#)). The hyoid bone serves as an indicator of the size and position related to surgical jaw movements. The hyoid bone may be considered the skeleton of the tongue, as these structures are directly related to each other. Mandibular setback osteotomy causes changes in the positions of the hyoid bone and tongue, and as a result, affects PAS ([2, 3](#)).

The present findings suggest that the hyoid bone moves downward and backward, following mandibular setback. While the backward movement of the hyoid bone in the mandibular setback group was due to the backward displacement of the mandible and tongue attached to the hyoid bone, the downward displacement seems to be a compensatory mechanism to maintain airway patency in the treated subjects. These findings are consistent with many previous studies, reporting that surgical correction of mandibular prognathism alters the position of the hyoid bone through downward repositioning, which carries the root of the tongue downward immediately after surgery ([12-18](#)).

On the other hand, there are conflicting views on the degree and duration of postoperative changes in the hyoid bone position. It has been suggested that downward or forward positioning of the base of the tongue is the compensatory mechanism allowing airway maintenance. After surgical setback of the mandible, some studies reported that the hyoid bone returned to its original position ([12, 13, 15](#)), while others stated that the bone never regained its original position ([3, 15-18](#)).

On the other hand, Tselnik and Pogrel (2000) observed early inferior and anterior movements of the hyoid bone immediately after mandibular setback ([3](#)). According to the present findings and others studies, the hyoid bone, which defines the ultimate position of the tongue, is more likely to never return to its original, presurgical position, as it may lead to insufficient posterior airway space and

Table 1. The Demographic Data of Class III Patients Treated with Surgery^a

Parameters		Group 1	Group 2	Group 3	P Value
Sex	Male	12 (30)	13 (32.5)	16 (40)	0.618 ^b
	Female	28 (70)	27 (67.5)	24 (60)	
Face height	Normal	14 (35)	17 (42.5)	14 (35)	0.129 ^b
	Long	18 (45)	12 (30)	9 (22.5)	
	Short	8 (20)	11 (27.5)	17 (42.5)	
Age		22.99 ± 4.53	22.73 ± 3.29	24.48 ± 2.53	0.064 ^c
Advancement		4.04 ± 1.78	-	4.33 ± 1.5	0.371 ^d
Setback		3.3 ± 1.49	4.35 ± 1.29	-	0.001 ^e

^aValues are expressed as mean ± SD or No. (%).

^bChi square test.

^cANOVA.

^dMann-Whitney U test.

^eStudent's t test.

Table 2. The Overall Changes in the Hyoid Bone Position in Different Groups

Parameters	Groups	T1 (Before)	T2 (After)	T1-T2 ^a	P Value
Hy to SN	Group 1	108.10 ± 11.62	109.52 ± 11.93	-1.42 ± 5.94A	0.138
	Group 2	106.40 ± 11.58	109.22 ± 10.33	-2.82 ± 6.25a	0.007
	Group 3	112.05 ± 11.50	111.62 ± 13.68	0.42 ± 5.90B	0.651
Hy to NL	Group 1	62.32 ± 8.21	62.90 ± 8.88	-0.57 ± 5.40A	0.505
	Group 2	61.10 ± 8.25	64.02 ± 7.66	-2.92 ± 6.00B	0.004
	Group 3	65.07 ± 8.01	65.70 ± 10.53	-0.62 ± 6.34A	0.537
Hy to ML	Group 1	11.97 ± 5.90	12.37 ± 5.25	-0.40 ± 5.15A	0.626
	Group 2	9.75 ± 4.52	12.17 ± 5.37	-2.42 ± 6.05B	0.015
	Group 3	13.10 ± 4.53	13.52 ± 5.61	-0.42 ± 5.01A	0.595
Hy to CV2ip	Group 1	54.07 ± 10.60	56.25 ± 7.62	-2.17 ± 11.60A	0.243
	Group 2	56.32 ± 7.42	56.30 ± 7.38	0.02 ± 3.78B	0.967
	Group 3	57.30 ± 7.60	57.75 ± 8.44	-0.45 ± 5.28B	0.593
Hy to CV4ip	Group 1	54.45 ± 6.60	53.95 ± 5.82	0.50 ± 5.56A	0.573
	Group 2	54.82 ± 5.55	52.85 ± 5.95	1.97 ± 3.07B	0.000
	Group 3	54.52 ± 5.17	54.05 ± 5.54	0.47 ± 3.74A	0.427
Hy to VRL	Group 1	31.57 ± 5.59	32.45 ± 4.86	-0.87 ± 3.86A	0.159
	Group 2	33.62 ± 5.74	29.85 ± 6.57	3.77 ± 3.88B	0.000
	Group 3	35.76 ± 16.56	34.70 ± 16.39	1.06 ± 3.95A	0.097
Hy to V	Group 1	15.30 ± 4.83	15.35 ± 4.85	-0.05 ± 5.40A	0.954
	Group 2	16.32 ± 4.96	16.32 ± 5.52	0.00 ± 3.75A	1.00
	Group 3	12.75 ± 1.93	12.37 ± 4.81	0.37 ± 4.55A	0.605

^aThe mean changes for each variable with at least a similar letter in the superscript (A or B) are not significantly different based on the ANCOVA model and Tukey's honest significant difference (HSD) test.

possible postoperative episodes of obstructive sleep apnea in patients following mandibular setback.

Table 3. The Hyoid Bone Positional Changes in Females from Different Groups

Parameters	Groups	T1 (Before)	T2 (After)	T1-T2*	P Value
Hy to SN	Group 1	103.50 ± 9.23	104.32 ± 8.62	-0.82 ± 5.52A	0.438
	Group 2	102.18 ± 10.14	105.07 ± 8.88	-2.89 ± 5.85B	0.016
	Group 3	107.96 ± 10.04	106.87 ± 12.40	1.08 ± 6.15A	0.397
Hy to NL	Group 1	59.53 ± 7.21	59.39 ± 7.22	0.14 ± 5.19A	0.885
	Group 2	58.67 ± 6.79	62.22 ± 6.92	-3.55 ± 5.22B	0.002
	Group 3	62.87 ± 7.68	62.46 ± 9.90	0.42 ± 6.15A	0.721
Hy to ML	Group 1	11.75 ± 5.65	11.32 ± 4.29	0.43 ± 5.14A	0.662
	Group 2	9.52 ± 3.60	13.00 ± 4.47	-3.48 ± 5.85B	0.005
	Group 3	12.75 ± 4.64	12.83 ± 5.00	-0.08 ± 4.80A	0.933
Hy to CV2ip	Group 1	52.32 ± 5.33	52.96 ± 5.18	-0.64 ± 4.06A	0.409
	Group 2	54.41 ± 7.41	53.67 ± 7.12	0.74 ± 3.16A	0.234
	Group 3	54.25 ± 7.23	54.62 ± 7.27	-0.37 ± 6.22A	0.770
Hy to CV4ip	Group 1	53.28 ± 5.66	52.21 ± 5.17	1.07 ± 4.63A	0.231
	Group 2	53.59 ± 5.25	51.04 ± 4.95	2.55 ± 2.93B	0.000
	Group 3	53.00 ± 4.55	52.33 ± 5.25	0.67 ± 3.73A	0.390
Hy to VRL	Group 1	30.78 ± 4.97	31.14 ± 4.27	-0.36 ± 3.80A	0.623
	Group 2	32.67 ± 4.93	27.92 ± 5.72	4.74 ± 3.17B	0.000
	Group 3	36.71 ± 21.09	35.08 ± 21.03	1.62 ± 3.68A	0.410
Hy to V	Group 1	13.68 ± 3.87	13.78 ± 4.13	-0.11 ± 5.53A	0.919
	Group 2	15.70 ± 4.84	14.70 ± 5.08	1.00 ± 3.37A	0.136
	Group 3	12.79 ± 1.84	12.04 ± 4.73	0.75 ± 4.14A	0.384

*The mean changes for each variable with at least a similar letter in the superscript (A or B) are not significantly different based on the ANCOVA model and Tukey's HSD test.

In the present study, we found that changes in the position of the hyoid bone were negligible in the bimaxillary advancement group. The findings in this group were in agreement with those reported by Liukkonen et al. (2002) and Aydemir et al. (2012), showing that the hyoid bone position remained unchanged following bimaxillary advancement (6, 19). However, our findings are in contrast to studies by Marsan et al. (20) and Foltan et al. (21), which showed the downward and backward movements of the hyoid bone following 2-jaw surgery.

In contrast to the present study, Efendiyeva et al. (2014) observed an early superior movement of the hyoid bone following bimaxillary orthognathic surgery (8). They suggested that this anterior movement was a physiological adaptation to preserve the airway patency. The possible cause of discrepancy between the results of previous studies may be the differences in the sample size and extent of maxillary advancement versus mandibular setback in these studies.

In the present study, we found no gender differences in the positional changes of the hyoid bone following bimaxillary advancement, which shows similar physiological adaptations in males and females following bimaxillary advancement. However, our findings are in contrast to a study by Samman et al. (11), which showed that the hyoid bone displaced backward only in women, while men did not show any significant differences in the hyoid bone position.

The stability of the hyoid bone position, both in vertical and horizontal dimensions following bimaxillary advancement, may be related to 2 factors. One factor is the extent of the mandibular posterior movement, which is more restricted in 2-jaw surgeries than single-jaw surgeries. This difference can directly affect the hyoid bone positional changes after surgery. The second factor may be the stability of airway dimensions, especially in the upper and lower pharyngeal regions, which is observed after 2-jaw surgery. This could reduce or even eliminate the need

Table 4. The Hyoid Bone Positional Changes in Males from Different Groups

Parameters	Groups	T1 (Before)	T2 (After)	T1-T2 ^a	P Value
Hy to SN	Group 1	118.83 ± 9.48	121.67 ± 9.63	-2.83 ± 6.87A	0.181
	Group 2	115.15 ± 9.51	117.22 ± 7.53	-2.69 ± 7.27A	0.027
	Group 3	118.19 ± 11.05	118.75 ± 12.66	-0.56 ± 5.56B	0.692
Hy to NL	Group 1	68.83 ± 6.75	71.08 ± 6.89	-2.25 ± 5.74A	0.202
	Group 2	66.15 ± 8.96	67.77 ± 8.04	-1.61 ± 7.43A	0.049
	Group 3	68.37 ± 7.54	70.56 ± 9.80	-2.19 ± 7.17A	0.241
Hy to ML	Group 1	12.50 ± 6.68	14.83 ± 6.55	-2.33 ± 4.85A	0.124
	Group 2	10.23 ± 6.15	12.46 ± 6.75	-2.23 ± 6.11A	0.034
	Group 3	13.62 ± 4.45	14.56 ± 6.44	-0.94 ± 5.43B	0.501
Hy to CV2ip	Group 1	58.17 ± 17.39	63.92 ± 6.97	-5.75 ± 20.42A	0.350
	Group 2	60.31 ± 5.88	61.77 ± 4.36	-1.46 ± 3.78B	0.275
	Group 3	61.87 ± 5.74	62.44 ± 8.05	-0.56 ± 3.63B	0.545
Hy to CV4ip	Group 1	57.17 ± 8.03	58.00 ± 5.38	-0.83 ± 7.36A	0.702
	Group 2	58.38 ± 5.48	56.61 ± 6.25	1.77 ± 3.14AB	0.039
	Group 3	56.81 ± 5.33	56.62 ± 5.07	0.19 ± 3.87A	0.849
Hy to VRL	Group 1	33.42 ± 6.69	35.50 ± 4.96	-2.08 ± 3.87A	0.089
	Group 2	35.61 ± 6.93	32.85 ± 6.61	2.77 ± 4.55A	0.018
	Group 3	34.34 ± 5.18	34.12 ± 4.44	0.22 ± 4.31B	0.842
Hy to V	Group 1	19.08 ± 4.87	19.00 ± 4.57	-0.08 ± 5.32A	0.958
	Group 2	17.61 ± 5.14	19.69 ± 5.01	-2.08 ± 3.77B	0.071
	Group 3	12.69 ± 2.12	12.87 ± 5.03	-0.19 ± 5.20A	0.887

^aThe mean changes for each variable with at least a similar letter in the superscript (A or B) are not significantly different based on the ANCOVA model and Tukey's HSD test.

for the compensatory downward movement of the hyoid bone following surgery. Maxillary advancement alone also showed no changes in the hyoid bone position, similar to bimaxillary advancement. However, no studies have yet reported the positional changes of the hyoid bone following maxillary advancement osteotomy.

4.1. Conclusions

Based on the findings, the hyoid bone position changes differently in various surgical operations. It was displaced downward and backward after mandibular retraction, whereas neither bimaxillary nor maxillary advancement could significantly change the hyoid position. Therefore, this finding could be helpful in the treatment of class III patients. If the patient has a history of snoring, breathing problems, or decreased airway size and requires mandibular setback, bimaxillary advancement is definitely preferred; this may in fact prevent future problems in the airway patency. Furthermore, there are no con-

cerns in either maxillary or bimaxillary advancement for class III patients.

References

1. Proffit WR, White RP, Sarver DM. Contemporary treatment of dento-facial deformity. 200. Mosby St Louis, Mo; 2003.
2. Kawamata A, Fujishita M, Arijji Y, Arijji E. Three-dimensional computed tomographic evaluation of morphologic airway changes after mandibular setback osteotomy for prognathism. *Oral Surg Oral Med Oral Pathol Oral Radiol Endod.* 2000;**89**(3):278-87. [PubMed: [10710450](#)].
3. Tselnik M, Pogrel MA. Assessment of the pharyngeal airway space after mandibular setback surgery. *J Oral Maxillofac Surg.* 2000;**58**(3):282-5. [PubMed: [10716109](#)] discussion 285-7.
4. Hwang S, Chung CJ, Choi Y, Huh JK, Kim KH. Changes of hyoid, tongue and pharyngeal airway after mandibular setback surgery by intraoral vertical ramus osteotomy. *Angle Orthod.* 2010;**80**(2):302-8. doi: [10.2319/040209-188.1](#). [PubMed: [19905855](#)].
5. Kitahara T, Hoshino Y, Maruyama K, In E, Takahashi I. Changes in the pharyngeal airway space and hyoid bone position after mandibular setback surgery for skeletal Class III jaw deformity in Japanese women. *Am J Orthod Dentofacial Orthop.* 2010;**138**(6):708 e1-10. doi: [10.1016/j.ajodo.2010.06.014](#). [PubMed: [21130322](#)] discussion 708-9.

6. Aydemir H, Memikoglu U, Karasu H. Pharyngeal airway space, hyoid bone position and head posture after orthognathic surgery in Class III patients. *Angle Orthod.* 2012;**82**(6):993-1000. doi: [10.2319/091911-597.1](https://doi.org/10.2319/091911-597.1). [PubMed: [22500578](https://pubmed.ncbi.nlm.nih.gov/22500578/)].
7. Cabral MB, de Freitas AC, de Araujo TM, Pena N, Brandao Filho RA. Effects of chin advancement surgery in hyoid bone and tongue positions and in the dimension of the oropharynx. *Dental Press J Orthod.* 2013;**18**(5):64-9. [PubMed: [24352390](https://pubmed.ncbi.nlm.nih.gov/24352390/)].
8. Efendiyeva R, Aydemir H, Karasu H, Toygar-Memikoglu U. Pharyngeal airway space, hyoid bone position, and head posture after bimaxillary orthognathic surgery in Class III patients: long-term evaluation. *Angle Orthod.* 2014;**84**(5):773-81. doi: [10.2319/072213-534.1](https://doi.org/10.2319/072213-534.1). [PubMed: [24601894](https://pubmed.ncbi.nlm.nih.gov/24601894/)].
9. Jacobson A, Jacobson RL. Radiographic Cephalometry: From Basics to 3-D Imaging, (Book/CD-ROM set). ;1995.
10. Graber LW, Vanarsdall RL, Vig KW, Huang GJ. Orthodontics-E-Book: Current Principles and Techniques. Elsevier Health Sciences; 2016.
11. Samman N, Tang SS, Xia J. Cephalometric study of the upper airway in surgically corrected class III skeletal deformity. *Int J Adult Orthodon Orthognath Surg.* 2002;**17**(3):180-90. [PubMed: [12353936](https://pubmed.ncbi.nlm.nih.gov/12353936/)].
12. Guven O, Saracoglu U. Changes in pharyngeal airway space and hyoid bone positions after body osteotomies and sagittal split ramus osteotomies. *J Craniofac Surg.* 2005;**16**(1):23-30. [PubMed: [15699641](https://pubmed.ncbi.nlm.nih.gov/15699641/)].
13. Kawakami M, Yamamoto K, Fujimoto M, Ohgi K, Inoue M, Kirita T. Changes in tongue and hyoid positions, and posterior airway space following mandibular setback surgery. *J Craniomaxillofac Surg.* 2005;**33**(2):107-10. doi: [10.1016/j.jcms.2004.10.005](https://doi.org/10.1016/j.jcms.2004.10.005). [PubMed: [15804589](https://pubmed.ncbi.nlm.nih.gov/15804589/)].
14. Gu G, Gu G, Nagata J, Suto M, Anraku Y, Nakamura K, et al. Hyoid position, pharyngeal airway and head posture in relation to relapse after the mandibular setback in skeletal Class III. *Clin Orthod Res.* 2000;**3**(2):67-77. [PubMed: [11168287](https://pubmed.ncbi.nlm.nih.gov/11168287/)].
15. Achilleos S, Krogstad O, Lyberg T. Surgical mandibular setback and changes in uvuloglossopharyngeal morphology and head posture: a short- and long-term cephalometric study in males. *Eur J Orthod.* 2000;**22**(4):383-94. [PubMed: [11029827](https://pubmed.ncbi.nlm.nih.gov/11029827/)].
16. Kim MA, Kim BR, Choi JY, Youn JK, Kim YJ, Park YH. Three-dimensional changes of the hyoid bone and airway volumes related to its relationship with horizontal anatomic planes after bimaxillary surgery in skeletal Class III patients. *Angle Orthod.* 2013;**83**(4):623-9. doi: [10.2319/083112-700.1](https://doi.org/10.2319/083112-700.1). [PubMed: [23311605](https://pubmed.ncbi.nlm.nih.gov/23311605/)].
17. Marsan G, Oztas E, Cura N, Kuvat SV, Emekli U. Changes in head posture and hyoid bone position in Turkish Class III patients after mandibular setback surgery. *J Craniomaxillofac Surg.* 2010;**38**(2):113-21. doi: [10.1016/j.jcms.2009.03.009](https://doi.org/10.1016/j.jcms.2009.03.009). [PubMed: [19447640](https://pubmed.ncbi.nlm.nih.gov/19447640/)].
18. Wang H, Qi S, Wang J, Cai Z, Li C. [Detection to changes in hyoid and tongue positions, and pharyngeal airway following mandibular setback surgery by cone beam CT]. *Hua Xi Kou Qiang Yi Xue Za Zhi.* 2012;**30**(6):650-4. [PubMed: [23330380](https://pubmed.ncbi.nlm.nih.gov/23330380/)].
19. Liukkonen M, Vahatalo K, Peltomaki T, Tiekso J, Happonen RP. Effect of mandibular setback surgery on the posterior airway size. *Int J Adult Orthodon Orthognath Surg.* 2002;**17**(1):41-6. [PubMed: [11934054](https://pubmed.ncbi.nlm.nih.gov/11934054/)].
20. Marsan G, Vasfi Kuvat S, Oztas E, Cura N, Susal Z, Emekli U. Oropharyngeal airway changes following bimaxillary surgery in Class III female adults. *J Craniomaxillofac Surg.* 2009;**37**(2):69-73. doi: [10.1016/j.jcms.2008.11.001](https://doi.org/10.1016/j.jcms.2008.11.001). [PubMed: [19117765](https://pubmed.ncbi.nlm.nih.gov/19117765/)].
21. Foltan R, Hoffmannova J, Donev F, Vlk M, Sedy J, Kufa R, et al. The impact of Le Fort I advancement and bilateral sagittal split osteotomy setback on ventilation during sleep. *Int J Oral Maxillofac Surg.* 2009;**38**(10):1036-40. doi: [10.1016/j.ijom.2009.06.001](https://doi.org/10.1016/j.ijom.2009.06.001). [PubMed: [19560899](https://pubmed.ncbi.nlm.nih.gov/19560899/)].