

# Efficacy and Safety of Piezosurgery Device in the Surgical Treatment of Oral Cancer

Marco Rossi,<sup>1</sup> Francesco Saverio Ludovichetti,<sup>1</sup> and Christian Bacci<sup>1,\*</sup>

<sup>1</sup>University of Padova, Padova, Italy

\*Corresponding author: Christian Bacci, University of Padova, Padova, Italy. Tel: +39-0498212040. E-mail: christian.bacci@unipd.it

Received 2015 July 30; Revised 2016 February 25; Accepted 2016 March 07.

## Abstract

**Introduction:** A new piezoelectric surgical device, a new system for cutting bone system, has recently been developed. It uses low-frequency ultrasonic vibrations to shape and cut bone.

**Case Presentation:** In this paper, we report the case of a 70-year-old woman affected by (G2, T1, M0) oral cancer treated with osteotomy performed using this piezoelectric device. The case presents the complete surgical excision of a fornix squamous cell carcinoma in which the marginal mandibulectomy was effected by a piezoelectric system.

**Conclusions:** People who have conditions involving bone that need to be surgically removed specifically nearby soft tissues or important structures (vessels, nerves, or brain), may benefit from this device. In the oral cavity, where the presence of essential structures may hinder safe osteotomy, the piezoelectric device allows the surgeon to cut bone without damaging nerves, glands, and vessels, even when in contact with them. The presence of angled inserts is also fundamental and facilitates osteotomies in areas that are unreachable by conventional cutters and burs.

**Keywords:** Piezoelectric Device, Oral Cancer, Oral Surgery, Head and Neck Surgery

## 1. Introduction

Cutting bone without injuring nearby soft tissues has always been a clinical challenge (1,2). Traditional mechanical instruments, such as drills, burs, and saws, have been widely used in clinics (3), but despite their effectiveness, they can be problematic to handle when used in proximity to soft tissues and important anatomical structures such as nerves and blood vessels (4,5). Recently, a new bone-cutting system has been developed: the piezoelectric surgical device (6). The piezoelectric device is a system for selectively cutting hard tissue that uses low-frequency ultrasonic vibrations (between 25 and 30 kHz) for osteotomy and bone-shaping (7). If the hand-piece insert accidentally comes into contact with soft tissues, such as blood vessels or nerves, injuries are prevented based on the different frequencies required to cut these tissues (8-10). This study discusses a case of squamous cell carcinoma of the fornix treated with a bony/mucosal exeresis of the left lower gum, where the mandibular bone osteotomy was effected using the piezoelectric system.

## 2. Case Presentation

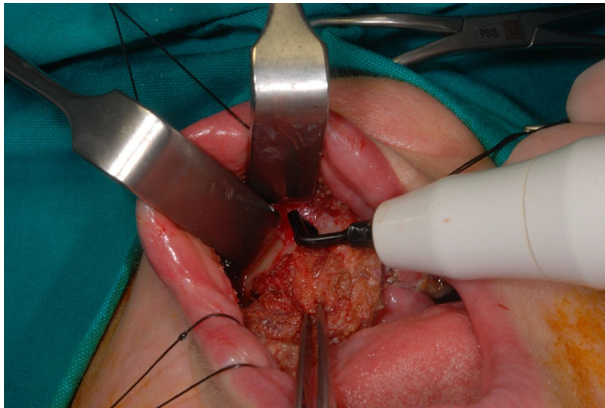
A 70-year-old woman presented a fornix oral lesion in March 2014. The patient did not show risk factors such as

history of smoking or alcohol use, but her past medical history showed oral lichen planus, a G2 squamous cell carcinoma of the left inferior alveolar mucosa in 2008, treated with CO2 laser excision, and a squamous carcinoma of the lower left lip in 2012, treated by surgical excision with clean margin. In the same surgery, an omolateral laterocervical selective neck dissection (level 1-2-3) was effected. Further histological examination revealed a squamous cell carcinoma (G2, T1, N0) with negative margins.

Because of the patient's clinical history, the differential diagnosis of the last lesion among other oral lesions, both its inflammatory nature and chemical or physical trauma nature, was straightforward. Nonetheless, an incisional biopsy was performed to confirm the clinical diagnosis.

The biopsy revealed a fornix squamous cell carcinoma diagnosis. To confirm this result, a facial bone and neck computed tomography (CT) scan was then performed in March 2014 both with and without contrast. CT examination showed that the carcinoma did not involve bone; therefore, a left marginal mucous-periosteum mandibulectomy was the surgery of choice. This was carried out 20 days after the positive biopsy.

After administering general anesthesia to the patient, the area affected by the carcinoma was incised with a cautery with a macroscopic margin of 1.5 cm behind the lesion. Then, the mandibular bone was exposed by elevation of a very small blunt dissection of a mucoperiosteal flap;



**Figure 1.** Osteotomy With Curved Cutter Mounted on the Piezoelectric Device

this approach was enabled by the use of the piezosurgery device.

Osteotomy of the corticocancellous part of the mandible was incised using the piezoelectric device (Esacrom®).

A straight insert was mounted on the piezoelectric device to axially cut the mandible bone and then an angle-shape insert was mounted to cut the base of the mandible fragment.

These different inserts allow, in a very simple and easy manner, areas to be reached that are otherwise difficult to access (Figure 1).

A straight chisel was then employed to complete the partial mandible exeresis.

A marginal block mandibulectomy ( $3 \times 1$  bone block) involving alveolar process and four teeth was performed; the alveolar and mental nerves were not involved in the cancer and so could be left in place.

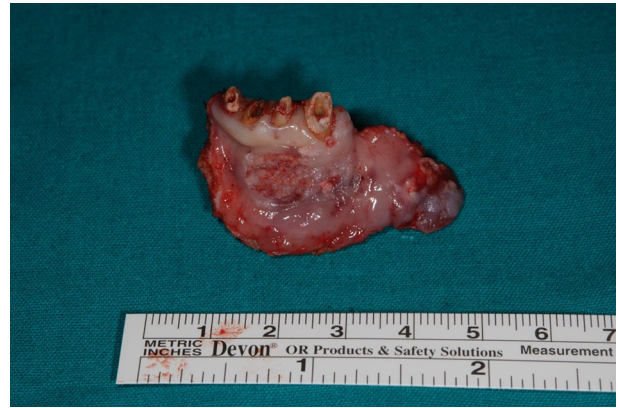Bone was not involved, as determined by the CT, but the tumor was close to the periosteum, so we decided to perform a marginal mandibulectomy, removing an amount of cortical bone, and leaving more than 1 cm of cortical bone (Figure 2).

Then the cancer, including the margins involving the bone, was excised and sent for intraoperative histological examination (Figure 3).

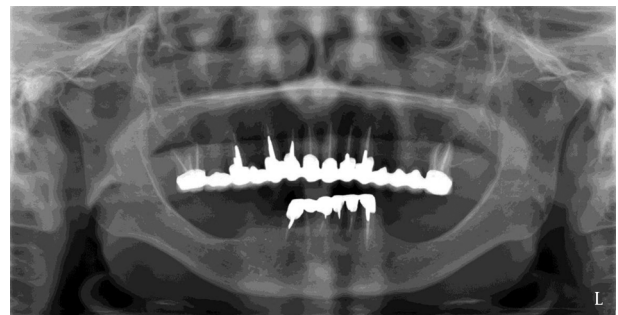
After the osteotomy, a round-shaped cutter was used to smooth the remaining sharp bone edges.

No lesions or traumatic injuries were evident following the excision.

Direct closure was achieved by direct suturing of the flap. Both intraoperative and then definitive histological examination of the removed section revealed a squamous cell carcinoma G1, T1, N0 with negative margins, no bone



**Figure 2.** Pretreatment Panoramic View



**Figure 3.** Squamous Cell Carcinoma Post-Operative Front View

involvement, and no angiolymphatic or perineural invasion. No complications appeared after the surgery, and neither the alveolar nor the mental nerve were impaired. The patient did not present feeding or phonation problems. The patient was declared disease-free on 21 October 2014.

### 3. Discussion

The key role of the piezosurgical tool in treatment of oral cavity cancer (T1; T2) is demonstrated by the complete surgical excision of the tumor mass with margins free of disease. In lesions occurring close to bone structures, removal of cortical bone is mandatory in order to obtain a healthy tissue margin. In the oral cavity, especially in the mandible, the proximity of important structures such as the lingual nerve, the Wharton's duct, the sublingual gland, the venous plexus, and the lingual artery often complicate osteotomies performed with traditional oscillating or rotating tools (i.e., burs and cutters). These instruments require the use of great care to protect the surrounding soft tissues, and they often require major soft tissues de-

tachments and surgical maneuvers that may be difficult and risky. The piezosurgery technique offers three important advantages:

1) The cutter harmonic oscillation does not create damage to surrounding soft tissues, even upon direct contact with them;

2) The angled cutters allow the execution of corticotomies in particular areas that are otherwise unreachable, such as the lingual cortical bone of the mandibular body; and

3) The piezoelectric device works at lower temperatures than conventional instruments that can create thermal damage to the bone.

### 3.1. Conclusion

The present report presents a technical alternative in the form of a piezoelectric surgical device for safe and simple osteotomy in the treatment of oral cancer. The piezoelectric device is widely applied in oral surgery but this is a rare report of its utility in the treatment of oral cancer.

Using piezosurgery in the surgical treatment of small carcinomas of the oral cavity allows easy performance of complex transoral marginal mandibulotomies and reduces the necessary dimensions of the mucoperiosteal dissection.

In this case, neither macroscopic nor microscopic nerve infiltration was present and so the patients did not experience any sensory disturbance. This result can be easily achieved using the piezoelectric device for selective cutting.

Long-term, controlled randomized studies are needed to support the use of this device in this branch of oral and maxillofacial surgery.

### Footnote

**Authors' Contribution:** Rossi performed the surgery, Ludovichetti collected the data and drafted the case study, and Bacci designed and drafted the study, and provided final approval.

### References

1. Jayawardene J, Choy D, Kuthubutheen J, Rajan GP. Piezosurgery applications in skull base surgery. *J Neurol Surg.* 2012;**73**:429.
2. Gleizal A, Bera JC, Lavandier B, Beziat JL. [Craniofacial approach for orbital tumors and ultrasonic bone cutting]. *J Fr Ophtalmol.* 2007;**30**(9):882-91. [PubMed: [18046270](#)].
3. Bacci C, Sivoletta S, Brunello G, Stellini E. Maxillary sinus bone lid with pedicled bone flap for foreign body removal: the piezoelectric device. *Br J Oral Maxillofac Surg.* 2014;**52**(10):987-9. doi: [10.1016/j.bjoms.2014.04.019](#). [PubMed: [24894711](#)].
4. Di Rienzo A, Iacoangeli M, Rychlicki F, Vecchia S, Scerrati M. Decompressive craniectomy for medically refractory intracranial hypertension due to meningoencephalitis: report of three patients. *Acta Neurochir (Wien).* 2008;**150**(10):1057-65. doi: [10.1007/s00701-008-0019-1](#). [PubMed: [18773140](#)].
5. Heredero Jung S, Dean Ferrer A, Solivera Vela J, Alamillos Granados F. Spheno-orbital meningioma resection and reconstruction: the role of piezosurgery and premolded titanium mesh. *Craniomaxillofac Trauma Reconstr.* 2011;**4**(4):193-200. doi: [10.1055/s-0031-1286113](#). [PubMed: [23205170](#)].
6. Vercellotti T, De Paoli S, Nevins M. The piezoelectric bony window osteotomy and sinus membrane elevation: introduction of a new technique for simplification of the sinus augmentation procedure. *Int J Periodontics Restorative Dent.* 2001;**21**(6):561-7. [PubMed: [11794567](#)].
7. Shelley ED, Shelley WB. Piezosurgery: a conservative approach to encapsulated skin lesions. *Cutis.* 1986;**38**(2):123-6. [PubMed: [3743126](#)].
8. Khambay BS, Walmsley AD. Investigations into the use of an ultrasonic chisel to cut bone. Part 1: Forces applied by clinicians. *J Dent.* 2000;**28**(1):31-7.
9. Khambay BS, Walmsley AD. Investigations into the use of an ultrasonic chisel to cut bone. Part 2: Cutting ability. *J Dent.* 2000;**28**(1):39-44. [PubMed: [10666960](#)].
10. Crosetti E, Battiston B, Succo G. Piezosurgery in head and neck oncological and reconstructive surgery: personal experience on 127 cases. *Acta Otorhinolaryngol Ital.* 2009;**29**(1):1-9. [PubMed: [19609375](#)].