

Cemento-ossifying Fibroma: Report of Two Interesting Cases

Imanimoghaddam, M.* Hoseini Zarch, S.H.** Javadian Langaroodi, A.***

Nemati, S. ****

*Associate Professor, Department of Oral and Maxillofacial Radiology, School of Dentistry and Dental Research Center, Mashhad University of Medical Sciences, Mashhad, Iran

**Assistant Professor, Department of Oral and Maxillofacial Radiology, School of Dentistry and Dental Research Center, Mashhad University of Medical Sciences, Mashhad, Iran

*** Assistant Professor, Department of Oral and Maxillofacial Radiology, School of Dentistry and Dental Research Center, Mashhad University of Medical Sciences, Mashhad, Iran

****Assistant Professor, Department of Oral and Maxillofacial Radiology, School of Dentistry, Guilan University of Medical Sciences, Guilan, Iran

ABSTRACT

Cemento-ossifying fibroma is a fibro-osseous lesion that has benign neoplastic behavior. We report two cases of cemento-ossifying fibroma (COF) and review the literature in order to study the imaging findings of COF. It is almost unavoidable that diagnosis of fibrous dysplasia from COF will be complicated by the fact that some pathologic features are shared by both lesions. So the final definitive diagnosis requires evaluation of the radiographic features.

Key Words: Cemento-ossifying fibroma, Fibroosseous lesion, Radiographic features, Case reports

INTRODUCTION

Cemento-ossifying fibroma is a neoplastic benign fibro-osseous lesion, which is limited to the jaws and facial bones. Microscopically, the lesion might be confused with fibrous dysplasia, and the final definitive diagnosis requires evaluation of the radiographic configuration.⁽¹⁾ These tumors occur in the third and fourth decades of life, with predilection for women.⁽²⁻⁵⁾ The majority of the lesions are found in the posterior region of the mandible.⁽²⁻⁴⁾ In general, ossifying

growth causes swelling and moderate deformation. The growth of the lesion can result in displacement of teeth or of the inferior alveolar canal. A significant point is that the outer cortical plate, although displaced and thinned, remains intact. The lamina dura of involved teeth usually is missing and resorption of teeth might occur.⁽⁶⁾ Differential diagnosis should be performed, preferably with other fibro-osseous lesions such as fibrous dysplasia and cemento-osseous dysplasia.⁽⁵⁾ The present study describes 2 cases of histopathologically confirmed cemento-ossifying fibroma and the interesting and unusual radiographic features of the lesions.

CASE REPORTS

Corresponding Author: Dr. A. Javadian Langaroodi, Address: School of Dentistry, Vakilabad Blvd, Mashhad, PO Box, 91735-984, Iran, Tel: +98 511 882 9501, E-mail: javadianla@mums.ac.ir
fibroma is an asymptomatic lesion until

Case 1

A 21-year-old man was referred to the Radiology Department because of a painless bony hard swelling in the buccal vestibule of the anterior region of the mandible. Clinically, the overlying mucosa of the lesion was intact. Displacement of the right central incisor and the left canine was evident.(Fig.1(A)). The patient reported that the lesion had formed 7 years previously and during the last 2 years, it had grown and in the left chin an asymmetry had revealed itself. In the panoramic view a mixed radiopaque lesion, extending from the left first molar to the right first molar of the mandible with well-defined borders, was evident. The lesion had displaced the teeth in the form of tilting, from the left first premolar to the second left premolar of the mandible. In addition, there was evidence of root resorption of the mandibular left canine and first premolar. The internal pattern of the lesion had a cotton wool appearance on the panoramic view and on the occlusal projection it was similar to ground glass. The axial CT projection revealed a considerable thinning and expansion of the buccal and lingual cortical plates (Fig. 1, B,C). At the same time a tissue sample was obtained for a histopathological study, which showed benign neoplastic proliferation of fibroblasts with fibroblastic vascular stroma. Furthermore, multiple sections of reactive osseous trabeculae and cemental tissues were seen.

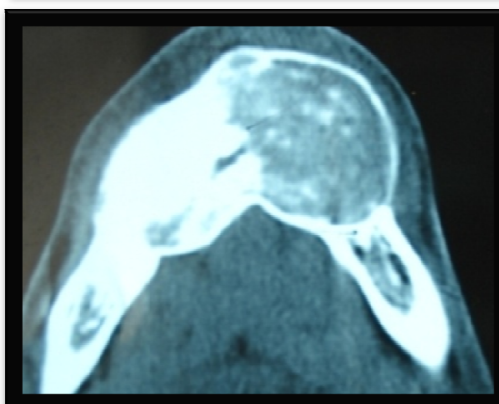
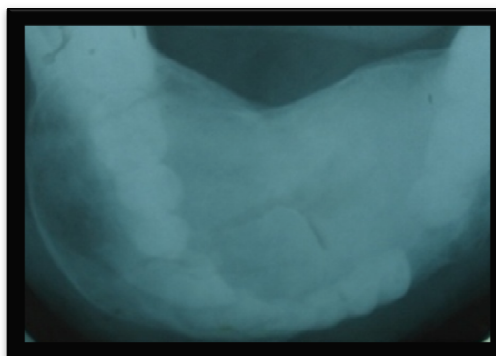
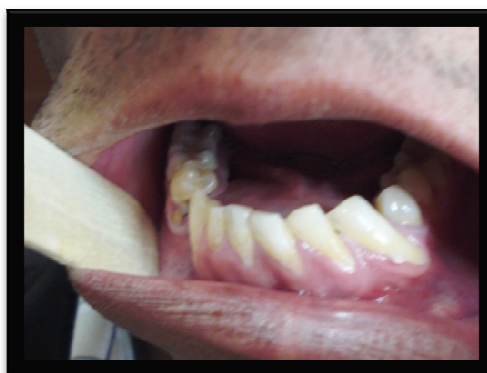

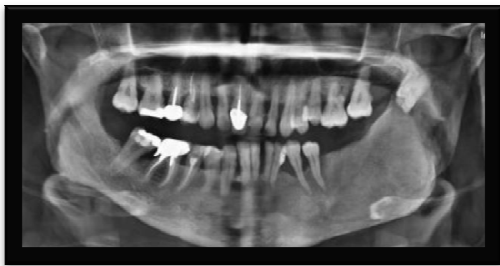
Fig.1(A-C):A: Clinical view of case 1, note to the mandibular anterior teeth displacement B: An occlusal view: the ground-glass appearance is evident.

C: An axial CT scan : note to the crossing of mandibular midline by lesion and severe buccal and lingual expansion.

The anatomopathologic diagnosis was cemento-ossifying fibroma. One year after enucleation of the lesion, the patient did not complain of any symptomatology.

Case 2

A 35-year-old woman complaining of a swelling on the left posterior region of the mandible referred to the Radiology Department. According to the patient's report, the swelling had been developed about two months previously and had gradually increased in size. On computed panoramic view (CR), a well-defined radiopaque lesion with a radiolucent rim, extending from the posterior to the left lateral border of the sigmoid notch of the mandible, was found. There was a significant expansion of the buccal cortical plate. Internal pattern of the lesion had a ground glass appearance and bodily displacement of the left mandibular third molar toward the coronoid process was evident. In addition, inferior and lateral displacement of the inferior alveolar canal



was seen (Fig. 2).

Fig.2: Computerized panoramic radiograph(CR) : note to the ground-glass appearance and bodily displacement of the mandibular third molar to the coronoid process.

Following an excisional biopsy, the specimen was histopathologically studied, which revealed a connective tissue containing varying amounts of abnormal

bone with irregular trabeculae. The lesion was infiltrated by calcification and cementoid tissue. The histopathologic diagnosis was cemento-ossifying fibroma. During follow-up appointments, the patient was asymptomatic and without radiographic alterations.

DISCUSSION

The age at diagnosis and sex distributions of patients with COFs have been reported.^(2-4,7) Similar to these studies, in our study, COF was found to occur in the third decade of life. Predilection is for the premolar-molar area of the mandible^(1-3,7) and for females,⁽¹⁻⁷⁾ although Krausen^[8] reported no particular sex predilection. It has also been reported in the maxilla,^(6, 7, 9, 10) ethmoidal⁽⁸⁾ and orbital regions,⁽¹¹⁾ petromastoid region⁽¹²⁾ and frontal⁽¹³⁾ and sphenoidal sinuses.⁽¹⁴⁾

In the present study, both cases occurred in the premolar-molar region of the mandible, one of which interestingly extended to the ramus and sigmoid notch of mandible and displaced the inferior alveolar canal laterally, and the other case crossed the midline of the mandible. In some cases the existence of a previous trauma on the area, tooth extractions and prior existence of periodontitis have been established as a possible etiological agent.^(5, 6, 9, 12) In the present study, the second patient had suffered from generalized periodontitis, which might be considered an etiological factor, consistent with some other studies. Clinically, COF presents as a slowly

enlarging and asymptomatic lesion, ^(2, 5, 6) simulating chronic periapical infectious pathology. ⁽⁵⁾ In the present study, both patients complained of a painless swelling on the involved region. There are some outstanding publications which have evaluated the aggressive behavior of these lesions. ^(8, 9) Radiographically, usually the bony cortices are expanded and intact ^(5, 6) and perforation of the cortex is rare. ⁽¹⁰⁾ In both our cases, the expanding cortex was intact. Root resorption and tooth displacement are common findings in these lesions; root resorption is seen in 11% and root divergence is recorded in 17% of cases. ⁽¹⁾ In the present study tooth displacement was revealed in both cases in the form of tilting in the first case and bodily movement in the second case, but root resorption was revealed in the first case.

Some multiple forms of COF have also been described in the literature. ⁽¹⁰⁾ In this study, both cases were solitary lesions. In the early stages cemento-ossifying fibroma appears as a radiolucent lesion with no evidence of internal radiopacities. As the tumor matures, there is increasing calcification so that the radiolucent area becomes flecked with opacities until ultimately the lesion appears as an extremely radiopaque mass. ⁽¹⁵⁾ Both cases in this study were manifested as a well-circumscribed lesion; one of them had a radiolucent rim in the periphery. In addition, internal pattern in the first case

was radiolucent-radiopaque and in another it had a radiopaque appearance.

In its histopathology it is typical to encounter a benign fibroblastic stroma with varying cellularity, although mitosis is rare. Within the fibrous stroma are mineralized tissue masses of basophilic aspect which correspond to osteoid or cementoid material. ⁽⁵⁾

Although it is a benign neoplasm, recurrences have been recorded. ^(1,4) Both cases showed no clinical or radiological evidence of recurrence after a one-year post-operative follow-up.

Cemento-ossifying fibroma is a central neoplasm of bone which has caused considerable controversy because of confusion regarding the criteria for its diagnosis. ⁽¹⁵⁾ The differential diagnosis of COF includes lesions with a mixed internal structure. Great difficulty may arise in differentiating ossifying fibroma from fibrous dysplasia. The boundaries of a COF lesion usually are better defined, and these lesions sometimes have a soft tissue capsule and cortex, while fibrous dysplasia usually blends in with the surrounding bone. ⁽¹⁶⁾

One additional important diagnostic feature is that the lesion tends to be concentric within the medullary part of the bone with outward expansion approximately equal in all directions, presenting as a round tumor mass. ⁽¹⁶⁾ In the second case of the present study, this centrifugal growth pattern was significantly evident, which caused severe

displacement of the left third molar as well as lateral and inferior displacement of the mandibular alveolar canal. Therefore, regarding the same pathologic features between cemento-ossifying fibroma and

REFERENCES

1. Eversole LR, Merrell PW, Strub D. Radiographic characteristic of central ossifying fibroma. *Oral surg oral med oral pathol* 1985; 59(5):522-527.
2. El Mofty SK. Cemento-ossifying fibroma and benign cementoblastoma. *Semin Diagn Pathol* 1999; 16(4):302-7.
3. Narvekar VN, Hegde KK, Hombal AG. Cemento-ossifying fibroma of mandible. *Australas Radiol* 2007; 51:176-9.
4. Eversole LR, Leider AS, Nelson K. Ossifying fibromas: a clinicopathologic study of sixty-four cases. *Oral Surg Oral Med Oral Pathol* 1985; 60(5):505-11.
5. Sanchis JM, Peñarrocha M, Balaguer JM, Camacho F. Cemento-ossifying mandibular fibroma: a presentation of two cases and review of the literature. *Med oral* 2004; 9(1):69-73.
6. Perez-Garcia S, Berini-Aytes L, Gay-Escoda C. Ossifying fibroma of the upper jaw: report of a case and review of literature. *Med Oral* 2004; 9(4):333-9.
7. Gunaseelan R, Anantanarayanan P, Ravindramohan E, Ranganathan K. Large cemento-ossifying fibroma of the maxilla causing proptosis: a case report. *Oral Surg Oral Med Oral Pathol Oral Radiol Endod* 2007; 104(4):21-5.
8. Krausen AS, Gulmen S, Zografakis G. Cementomas II. Aggressive cemento-fibrous dysplasia, the radiographic criteria such as growth pattern and presence of a well-defined border with or without a radiolucent rim in cemento-ossifying fibroma may be helpful in the diagnosis. *Arch Otolaryngol* 1977; 103(6):371-73.
9. Weing BL, Sciubba JJ, Cohen ,Goldstein MN, Abramson AL. A destructive maxillary cemento-ossifying fibroma following maxillofacial trauma. *Laryngoscope* 1984; 94:810-15.
10. Takeda Y, Fukioka Y. Multiple cemento-ossifying fibroma. *Int J Oral Maxillofac Surg* 1987(3);16:368-71.
11. Margo CE, Ragsdale BD, Perman KI, Zimmerman LE, Sweet DE. Psammomatoid (juvenile) ossifying fibroma of the orbit. *Ophthalmology* 1982;92:150-159.
12. Brademann G, Werner JA, Jänig U, Mehdorn HM, Rudert H. Cemento-ossifying fibroma of the petromastoid region: case report and review of the literature. *Laryngol Otol J* 1997; 111:152-5.
13. Abou-Elhamd KE. Frontal sinus cementifying ossifying fibroma. *Saudi Med J* 2005; 26(3):470-2.
14. Cheng C, Takahashi H, Yao K, Nakayama M, Makoshi T, Nagai H, and et al. Cemento-ossifying fibroma of maxillary and sphenoid sinuses: case report and literature review. *Acta Otolaryngol Suppl* 2002; 547:118-22.
15. Sarwar HG, Jindal MK, Ahmad SS. Cemento-ossifying fibroma-a rare case. *J Indian SOS Pedod Prev Dent* 2008; 26(3):128-31.
16. White SC, Pharoah MJ. *Oral Radiology*. 6th ed. China: Mosby Co; 2009.p:428-42.