



Successful Treatment of Necrosed Primary Molars Using LSTR Technique by a New Combination of Antibiotics: A Case Series



Rezvan Rafatjou¹, Sanaz Afzal Soltani^{2*}

Abstract

Introduction: In this study we used combination of amoxicillin, metronidazole and clindamycin for treatment of 3 patients with infected primary molars until eruption of the first molars. **Materials and Methods:** A single session LSTR was done using combination of ciprofloxacin, metronidazole and andclindamycin at the ratio of 1:1:1. **Conclusions:** After 12- to 13-month follow-ups, the combination can greatly help save hopeless infected primary molars before eruption of permanent first molars due to effective space maintenance.

*Correspondence to
Sanaz Afzal Soltani,
Email: dr.s.afzalsoltani@gmail.com
Tel: +989127724973

Keywords: LSTR, primary molars, othermix

Received June 21, 2018
Accepted Oct. 9, 2018
Published Dec. 27, 2018

Citation: Rafatjou R, Afzal Soltani S. Successful treatment of necrosed primary molars using LSTR technique by a new combination of antibiotics: a case series. Avicenna J Dent Res. 2018;10(4):143-147. doi: 10.34172/ajdr.2018.28.

Background

Bacteria play an important role in initiation, progression and persistence of apical periodontitis (1). During pulp inflammation, diverse oral and foodborne microorganisms invade the pulp space, form biofilm on canal walls, and infiltrate the dentinal tubules (2).

Root canal infections are polymicrobial in nature, consisting of both aerobic and anaerobic species. Recently molecular approaches have confirmed the existence of mixed infections with predominant anaerobic bacteria in both permanent and infected primary teeth (3,4). These bacteria should be eliminated to ensure a successful outcome (1,5). Endodontic treatment of primary teeth with necrotic pulps is routinely done in dental practices (6). Bacteria present mainly in the root canal and on the superficial layer of the canal wall may be easily removed by conventional endodontic treatment (7). Due to the management of uncooperative children's behavior and typical primary tooth morphology (tortuous root canals, presence of multiple accessory canals, ramifications, and ample medullary bone spaces that favor dissemination of infection), the effective eradication of microorganisms during the root canal treatment procedure is often challenging to the clinician (8-11). Several studies have been conducted on the use antibiotics as root canal irrigants and medicaments named LSTR (lesion sterilization and tissue repair therapy). Because of complexity of the root canal infections, it is unlikely that any single antibiotic could result in an effective sterilization of the canal even if it has a broad antibacterial spectrum. The combination that appears to be promising consists of metronidazole,

Highlights

- ▶ This study reports three cases of single session LSTR (using combination of clindamycin, ciprofloxacin and metronidazole) for infected primary molars
- ▶ The only side effect observed was early root resorption
- ▶ It seems to greatly assist in saving hopeless infected primary molars

ciprofloxacin and minocycline (4,5), but pigmentation is a well-recognized adverse effect of minocycline therapy (12,13).

Therefore double antibiotic pastes without minocycline or substitution of minocycline with another antibiotic (clindamycin, cefaclor, or amoxicillin) was suggested to be used for efficient root canal disinfection during the pulp regeneration (5).

Methods

In this study the combination of ciprofloxacin, metronidazole and clindamycin was used for treatment of 3 patients with infected primary molars referred to pediatric department of dentistry school, Hamadan, Iran, to receive necessary services as long as possible or until eruption of the first molars.

Preparation of antibacterial paste: Commercially available chemotherapeutic agents ciprofloxacin 500 mg (Farabi, Iran), metronidazole 250 mg (Pars Darou, Iran), clindamycin 150 mg (Soha, Iran) were pulverized into powder after the removal of the enteric coating on the drugs and kept separately to prevent exposure to light and

¹Assistant Professor, Department of Pediatric Dentistry, Hamadan University of Medical Sciences, Hamadan, Iran. ²Assistant Professor, Department of Pediatric Dentistry, Alborz University of Medical Sciences, Karaj, Iran.

moisture. These powdered drugs were used in a ratio of 1:1:1 as the 3mix. One increment of each powdered drug was mixed with propylene glycol to form an ointment just before use.

Three healthy 3- to 6-year-old children without any significant medical discomfort with irreversible pulpitis in primary molars were enrolled in the study. Tooth with advanced internal or external root resorption or with unrestorable crowns because of extended caries were excluded.

Before beginning of the treatments, informed consent for participation in the study was obtained from parents and they were asked to attend follow-up meetings every 3 month or whenever there was any symptom.

Case 1

Our first case was left primary second mandibular molar in a 4-year boy. Buccal abscess was found in clinical examination. Periapical radiography showed a large radiolucency in the furcation area and around mesial root. At examination there was no complaint of pain or sign of malaise. Patient poor cooperation during examination, radiography and start of treatment indicated the need for single session treatment.

Informed consent was obtained and inferior alveolar nerve block injection was applied. Access cavity was prepared and necrotic pulp remnants and debris were extirpated by means of barbed broach and canal preparation was done to 1 mm shorter than radiographic apex by means of K files up to number 30. Root canals were irrigated with normal saline and dried by paper cones of suitable size. An LSTR procedure was performed; antibiotics were pushed in canals as deep as possible within the working length by plunger. Reinforced zinc oxide eugenol was used for pulp chamber obturation and SSC was placed. During follow-up sessions at 3-month intervals, clinical symptoms were normal, there was no pain or sensitivity to percussion and mobility was normal. Radiographic examinations after 3 and 13 months showed normal condition of the tooth and normal development of successor tooth (Figure 1). A slight remaining radiolucency around the mesial root of the teeth is detectable but because the size of radiolucency was getting smaller over time and the borders of subsequent tooth's bud was intact, the treatment, though temporarily, was successful until eruption of the first permanent molar.

Case 2

A 4-year-old girl was examined for the chief complaint of vestibular abscess and history of spontaneous pain of right primary second mandibular molar. The tooth had moderate grade of mobility and the child's cooperation was poor. Radiographic examination showed a large area of radiolucency indicating severe alveolar bone resorption due to the periapical infection of the tooth. After obtaining an informed consent, LSTR procedure

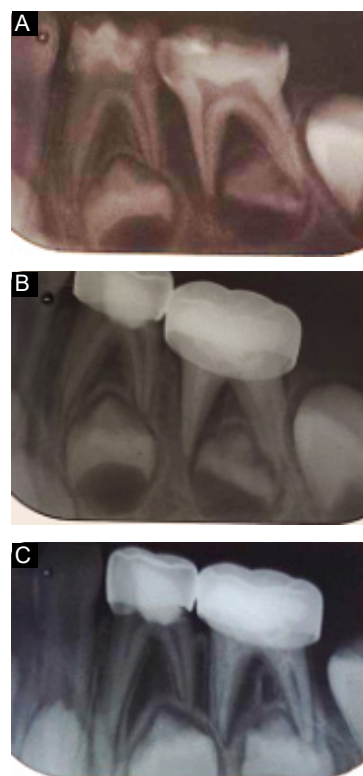


Figure 1. Lesion Sterilization and Tissue Repair Therapy for Primary First Mandibular Molar. A: Periapical radiography shows a large radiolucency in the furcation area and around mesial root; B,C: Radiographic examinations after 3 and 13 months show normal condition of the tooth and normal development of successor tooth. A slight remaining radiolucency around the mesial root of the teeth is detectable but the size of radiolucency is getting smaller over time and the borders of subsequent tooth's bud is intact.

was done similar to case 1. At 3-month follow-ups no pain or abnormal signs were detected throughout clinical observations. Radiographic examination after 12 months showed normal development of the second premolar bud but early resorption of the primary second mandibular molar was seen. However, the first permanent molar was in the last stages of preeruption phase indicating the emergence through the soft tissue within 6 months, which facilitated space maintenance of the second primary molar if necessary (Figure 2). Initially, there was no radiographic sign of second premolars bud. After 1 year of treatment, as it was visible in the radiography the tooth's bud was normally developing, indicating that it was not affected by the infection of the primary second molar. Although early root resorption in the second primary molar was visible, the underlying tooth bud had radiographical sign of normal developing condition and the first permanent molar was erupting normally. As a result, our therapeutic goals were normal development and eruption of the permanent second premolar and first molar in the area which was well underway.

Case 3

A 3.5-year-old boy was examined for the chief complaint

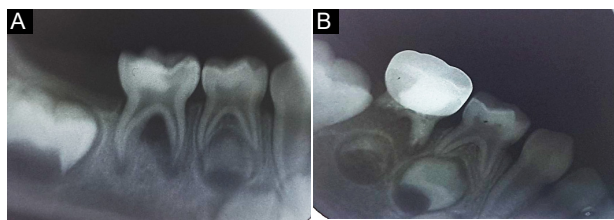


Figure 2. Lesion Sterilization and Tissue Repair Therapy for Primary Second Mandibular Molar. A: Radiographic examination shows a large area of radiolucency around the mesial root of the tooth; B: 12 months after treatment, although early root resorption in the second primary molar is visible, but radiographical sign of the underlying tooth bud indicates normal developing condition and first permanent molar is erupting normally.

of vestibular abscess and history of spontaneous pain of left maxillary first primary molar. The child's cooperation was poor. Radiographic examination showed mild internal root resorption. After obtaining the informed consent, LSTR procedure was done similar to case 1. At 3-month follow-ups no pain or abnormal signs were clinically detected. Radiographic examination after 12 months showed normal development of the subsequent first premolar bud and the primary internal resorption was not seen to progress (Figure 3).

Discussion

Pulp therapy for primary teeth is difficult for certain reasons like difficulty managing behavior management, differences in the morphology of the primary teeth, complexity of root canals, desired timely resorption, and difficulties with root canal filling materials. The goal of successful pulpectomy is to eliminate all bacteria in the root canal systems (7). The Cariology Research Unit of the School of Dentistry, Niigata University, Japan developed the concept of LSTR, which is a non-instrumental endodontic treatment that employs a mixture of antibacterial drugs in a propylene glycol vehicle for the disinfection of carious lesions (14). LSTR has no mechanical instrumentation. This prevents too much enlargement of the root canals, reduces chair time and requires only one treatment visit (15). Clinical studies have confirmed the potency of triple antibiotic paste (TAP, a combination of metronidazole, ciprofloxacin, and minocycline) as the disinfectant during endodontic treatments (16, 17). These antibacterial drugs were selected based on the studies to understand the target bacteria in LSTR (6). Metronidazole was selected as an appropriate drug against obligate anaerobes, which comprise the majority of bacteria in the root canal system (10). Ciprofloxacin, a bactericidal agent effective against gram-negative species and minocycline, a bacteriostatic agent effective against a wide range of microorganisms, were added to metronidazole (18).

Nanda et al reported that the use of 3Mix or other Mix could be a good alternative to conventional pulpectomy and root filling (7).

Takushige et al evaluated the effectiveness of LSTR for

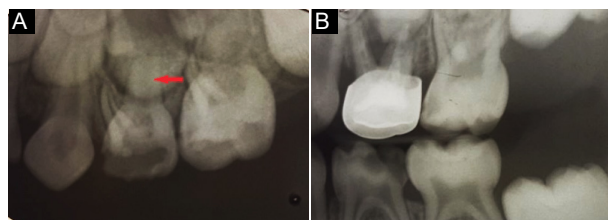


Figure 3. Lesion Sterilization and Tissue Repair Therapy for Left Maxillary First Primary Molar. A: Radiographic examination shows carious enamel and dentin with pulpal involvement in the maxillary first primary molar and also mild internal root resorption (arrow); B: 12 months after treatment, normal development of the subsequent first premolar bud is seen and the primary internal resorption of the first primary molar is not seen to progress.

the primary teeth. They found that in 87 cases after a follow-up period of 680 days, the symptoms of the infected primary teeth such as abscess, gingival fistulae and pain were relieved and the teeth remained asymptomatic until exfoliation (19).

Prabhakar et al found that endodontic treatment using antibacterial mix (a combination of ciprofloxacin, metronidazole and minocycline) in the primary teeth showed good clinical and radiographic results. They also found that all the treated cases were clinically and radiographically successful with removal of necrotic coronal and accessible radicular pulp tissue when compared with only coronal pulp removal (20).

Nakornchai et al reported that TAP could be successfully used as a root canal treatment agent in the pulpally involved primary teeth. They concluded that the simple and short procedures of 3mix could be superior to other materials used for root canal treatment in children (15).

As mentioned above, one of the ingredients of the common TAP is minocycline which is a semisynthetic derivative of tetracycline, a group of bacteriostatic broad-spectrum antibiotics that are effective against a wide range of microorganisms (10). It binds to calcium ions via chelation to form an insoluble complex. Therefore, the minocycline incorporated into the tooth matrix leads to discoloration (21). Thereafter, many efforts were made to reduce tooth discoloration by using TAP. In addition, substituting minocycline with an alternative antibiotic could reduce tooth discoloration and result in effective disinfection of the root canal (22). Trop et al (23) suggested that Arestin could be used as a substitute for minocycline to markedly reduce discoloration. Thomson and Kahler substituted amoxicillin for minocycline to avoid discoloration in their reported case (24). Also the bactericidal efficacies of the mixture of ciprofloxacin and metronidazole plus cefaclor, cefroxadine, fosfomycin or rokitamycin have been compared with minocycline containing type of 3mix paste (25). Later, severe tooth color change was reported after 1 day application of TAP containing cefaclor (22). In the new edition of *Textbook of Pediatric Dentistry* (26), clindamycin has been introduced as a recommended substitute for minocycline because of

its tendency to stain teeth (27). The disinfecting activity of clindamycin as temporary dressing of the root canals before obturation of canal has been investigated by Molander and Dahlen (28). In their study the clindamycin paste was successfully used to eliminate bacterial growth in 21 of the 25 teeth examined by the 14th day; however, they reported no advantage for clindamycin over conventional root canal dressings (10,28). There is a comparison between antibacterial effect of clindamycin and tetracycline in a bovine dentinal tubule model using an agar diffusion test. They observed that the clindamycin significantly reduced the amount of viable bacteria compared with tetracycline (10, 29). In our reported cases, infected primary molars were treated using a combination of ciprofloxacin-metronidazole and clindamycin, as a substitute of minocycline. Furthermore, the long-term prognosis of the treated teeth was questionable but the treatment can be considered successful given lack of any symptom, radiographic signs of normal developing successor tooth buds and objective of the treatment (preservation of questionable or hopeless primary molars in uncooperative children as long as possible or at least until eruption of permanent first molars).

Conclusions

In this study we reported three cases of single session LSTR (using combination of clindamycin, ciprofloxacin and metronidazole) for infected primary molars in uncooperative patients at the age of 3.5-4. After 12- to 13-month follow-ups normal signs and symptoms were detected. Only in one case there was radiographic sign of early root resorption of the treated tooth (case 2) without any radiographic sign of underlying tooth bud involvement. Longer follow-up periods are needed to assess erupted successor teeth and ensure the usefulness of this treatment procedure. However, it seems to greatly assist in saving hopeless infected primary molars before eruption of permanent first molars due to effective space maintenance.

Authors' Contribution

All authors contributed equally to this work.

Ethical Statement

Not applicable.

Conflict of Interest Disclosures

The authors declare that they have no conflict of interests.

Funding

The study was self-funded.

Acknowledgments

The authors would like to thank pediatric department of Hamadan University of medical sciences for their support.

References

- Jaya AR, Praveen P, Anantharaj A, Venkataraghavan K, Rani PS. In vivo evaluation of lesion sterilization and tissue repair in primary teeth pulp therapy using two antibiotic drug combinations. *J Clin Pediatr Dent*. 2012;37(2):189-91.
- Duggan D, Arnold RR, Teixeira FB, Caplan DJ, Tawil P. Periapical inflammation and bacterial penetration after coronal inoculation of dog roots filled with RealSeal 1 or Thermafil. *J Endod*. 2009;35(6):852-7. doi: [10.1016/j.joen.2009.03.050](https://doi.org/10.1016/j.joen.2009.03.050).
- Schafer E, Olthoff G. Effect of three different sealers on the sealing ability of both thermafil obturators and cold laterally compacted Gutta-Percha. *J Endod*. 2002;28(9):638-42. doi: [10.1097/00004770-200209000-00003](https://doi.org/10.1097/00004770-200209000-00003).
- Pinky C, Shashibhushan KK, Subbareddy VV. Endodontic treatment of necrosed primary teeth using two different combinations of antibacterial drugs: an in vivo study. *J Indian Soc Pedod Prev Dent*. 2011;29(2):121-7. doi: [10.4103/0970-4388.84684](https://doi.org/10.4103/0970-4388.84684).
- Kayalvizhi G, Subramaniyan B, Suganya G. Topical application of antibiotics in primary teeth: an overview. *J Dent Child (Chic)*. 2013;80(2):71-9.
- Carrotte P. Endodontic treatment for children. *Br Dent J*. 2005; 198(1): 9-15.
- Nanda R, Koul M, Srivastava S, Upadhyay V, Dwivedi R. Clinical evaluation of 3 Mix and Other Mix in non-instrumental endodontic treatment of necrosed primary teeth. *J Oral Biol Craniofac Res*. 2014;4(2):114-9. doi: [10.1016/j.jobcr.2014.08.003](https://doi.org/10.1016/j.jobcr.2014.08.003).
- da Silva LA, Nelson-Filho P, Faria G, de Souza-Gugelmin MC, Ito IY. Bacterial profile in primary teeth with necrotic pulp and periapical lesions. *Braz Dent J*. 2006;17(2):144-8.
- Parasuraman VR, Muljibhai BS. 3Mix-MP in Endodontics-An overview. *J Dent Med Sci*. 2012;3(1):36-45. doi: [10.9790/0853-0313645](https://doi.org/10.9790/0853-0313645).
- Mohammadi Z, Abbott PV. On the local applications of antibiotics and antibiotic-based agents in endodontics and dental traumatology. *Int Endod J*. 2009;42(7):555-67. doi: [10.1111/j.1365-2591.2009.01564.x](https://doi.org/10.1111/j.1365-2591.2009.01564.x).
- Peters OA, Laib A, Gohring TN, Barbakow F. Changes in root canal geometry after preparation assessed by high resolution computed tomography. *J Endod*. 2001;27:1-6.
- Eisen D, Hakim MD. Minocycline-induced pigmentation. Incidence, prevention and management. *Drug Saf*. 1998;18(6):431-40. doi: [10.2165/00002018-199818060-00004](https://doi.org/10.2165/00002018-199818060-00004).
- Dodd MA, Dole EJ, Troutman WG, Bennahum DA. Minocycline-associated tooth staining. *Ann Pharmacother*. 1998;32(9):887-9. doi: [10.1345/aph.17397](https://doi.org/10.1345/aph.17397).
- Burrus D, Barbeau L, Hodgson B. Treatment of abscessed primary molars utilizing lesion sterilization and tissue repair: literature review and report of three cases. *Pediatr Dent*. 2014;36(3):240-4.
- Nakornchai S, Banditsing P, Visetratana N. Clinical evaluation of 3Mix and Vitapex as treatment options for pulpally involved primary molars. *Int J Paediatr Dent*. 2010;20(3):214-21. doi: [10.1111/j.1365-263X.2010.01044.x](https://doi.org/10.1111/j.1365-263X.2010.01044.x).
- Shivashankar VY, Johns DA, Vidyanath S, Kumar MR. Platelet Rich Fibrin in the revitalization of tooth with necrotic pulp and open apex. *J Conserv Dent*. 2012;15(4):395-8. doi: [10.4103/0972-0707.101926](https://doi.org/10.4103/0972-0707.101926).
- Vijayaraghavan R, Mathian VM, Sundaram AM, Karunakaran R, Vinodh S. Triple antibiotic paste in root canal therapy. *J Pharm Bioallied Sci*. 2012;4(Suppl 2):S230-3. doi: [10.4103/0975-7406.100214](https://doi.org/10.4103/0975-7406.100214).
- Windley W 3rd, Teixeira F, Levin L, Sigurdsson A, Trope M. Disinfection of immature teeth with a triple antibiotic paste. *J Endod*. 2005;31(6):439-43.
- Takushige T, Cruz EV, Asgor Moral A, Hoshino E. Endodontic

- treatment of primary teeth using a combination of antibacterial drugs. *Int Endod J.* 2004;37(2):132-8.
20. Prabhakar AR, Sridevi E, Raju OS, Satish V. Endodontic treatment of primary teeth using combination of antibacterial drugs: an in vivo study. *J Indian Soc Pedod Prev Dent.* 2008;26 Suppl 1:S5-10.
 21. Kim JH, Kim Y, Shin SJ, Park JW, Jung IY. Tooth discoloration of immature permanent incisor associated with triple antibiotic therapy: a case report. *J Endod.* 2010;36(6):1086-91. doi: [10.1016/j.joen.2010.03.031](https://doi.org/10.1016/j.joen.2010.03.031).
 22. Park HB, Lee BN, Hwang YC, Hwang IN, Oh WM, Chang HS. Treatment of non-vital immature teeth with amoxicillin-containing triple antibiotic paste resulting in apexification. *Restor Dent Endod.* 2015;40(4):322-7. doi: [10.5395/rde.2015.40.4.322](https://doi.org/10.5395/rde.2015.40.4.322).
 23. Trope M. Treatment of the immature tooth with a non-vital pulp and apical periodontitis. *Dental Clinics of North America* 2010;54:313-24.
 24. Thomson A, Kahler B. Regenerative endodontics--biologically-based treatment for immature permanent teeth: a case report and review of the literature. *Aust Dent J.* 2010;55(4):446-52.
 25. Hoshino E, Kurihara-Ando N, Sato I, Uematsu H, Sato M, Kota K, et al. In-vitro antibacterial susceptibility of bacteria taken from infected root dentine to a mixture of ciprofloxacin, metronidazole and minocycline. *Int Endod J.* 1996;29(2):125-30.
 26. Casamassimo PS, Fields HW Jr, McTigue DJ, Nowak A. *Pediatric Dentistry: Infancy Through Adolescence.* 5th ed. Saunders; 2013.
 27. Kim B, Song MJ, Shin SJ, Park JW. Prevention of tooth discoloration associated with triple antibiotics. *Restor Dent Endod.* 2012;37(2):119-22. doi: [10.5395/rde.2012.37.2.119](https://doi.org/10.5395/rde.2012.37.2.119).
 28. Molander A, Dahlen G. Evaluation of the antibacterial potential of tetracycline or erythromycin mixed with calcium hydroxide as intracanal dressing against *Enterococcus faecalis* in vivo. *Oral Surg Oral Med Oral Pathol Oral Radiol Endod.* 2003;96(6):744-50. doi: [10.1016/s1079210403003615](https://doi.org/10.1016/s1079210403003615).
 29. Boltacz-Rzepakowska E, Pawlicka H. Radiographic features and outcome of root canal treatment carried out in the Lodz region of Poland. *Int Endod J.* 2003;36(1):27-32.